

A3

100

No.	Date	Description
-----	------	-------------

Case No.	Case Name	Case Type	Case Status	Case Date	Case Time	Case Location	Case Description	Case Notes	Case Comments
1	John Doe	Medical	Open	2023-01-01	10:00	Room 101	John Doe, 45 years old, male, presented with chest pain and shortness of breath. Vital signs: BP 120/80, HR 90, RR 20, SpO2 98%.	ECG showed sinus tachycardia. Chest X-ray showed clear lung fields.	Admitted to the medical ward for further observation and treatment.
2	Jane Smith	Medical	Closed	2023-01-02	14:30	Room 102	Jane Smith, 32 years old, female, presented with abdominal pain and nausea. Vital signs: BP 110/70, HR 75, RR 18, SpO2 99%.	ECG showed normal sinus rhythm. Abdominal ultrasound showed no abnormalities.	Discharged home with oral painkillers and instructions to return if symptoms worsen.
3	Michael Brown	Medical	Open	2023-01-03	08:15	Room 103	Michael Brown, 68 years old, male, presented with dizziness and weakness. Vital signs: BP 130/90, HR 100, RR 22, SpO2 97%.	ECG showed sinus tachycardia. Blood tests showed elevated creatinine levels.	Admitted to the medical ward for further observation and treatment.
4	Sarah Johnson	Medical	Closed	2023-01-04	11:45	Room 104	Sarah Johnson, 28 years old, female, presented with fever and cough. Vital signs: BP 100/60, HR 85, RR 16, SpO2 96%.	ECG showed normal sinus rhythm. Chest X-ray showed infiltrates in the right lung.	Admitted to the medical ward for further observation and treatment.
5	David Wilson	Medical	Open	2023-01-05	09:30	Room 105	David Wilson, 55 years old, male, presented with chest pain and sweating. Vital signs: BP 140/90, HR 110, RR 24, SpO2 95%.	ECG showed ST-segment elevation. Blood tests showed elevated troponin levels.	Admitted to the medical ward for further observation and treatment.
6	Emily Davis	Medical	Closed	2023-01-06	13:00	Room 106	Emily Davis, 38 years old, female, presented with headache and vomiting. Vital signs: BP 120/80, HR 80, RR 18, SpO2 98%.	ECG showed normal sinus rhythm. CT scan of the head showed no abnormalities.	Discharged home with oral painkillers and instructions to return if symptoms worsen.
7	Robert Miller	Medical	Open	2023-01-07	07:45	Room 107	Robert Miller, 72 years old, male, presented with confusion and disorientation. Vital signs: BP 150/100, HR 120, RR 26, SpO2 94%.	ECG showed sinus tachycardia. Blood tests showed elevated ammonia levels.	Admitted to the medical ward for further observation and treatment.
8	Lisa Anderson	Medical	Closed	2023-01-08	15:15	Room 108	Lisa Anderson, 42 years old, female, presented with joint pain and swelling. Vital signs: BP 110/70, HR 75, RR 18, SpO2 99%.	ECG showed normal sinus rhythm. Blood tests showed elevated uric acid levels.	Discharged home with oral painkillers and instructions to return if symptoms worsen.
9	Christopher Lee	Medical	Open	2023-01-09	10:30	Room 109	Christopher Lee, 50 years old, male, presented with chest pain and shortness of breath. Vital signs: BP 130/80, HR 95, RR 20, SpO2 97%.	ECG showed sinus tachycardia. Chest X-ray showed clear lung fields.	Admitted to the medical ward for further observation and treatment.
10	Amanda White	Medical	Closed	2023-01-10	12:00	Room 110	Amanda White, 30 years old, female, presented with fever and cough. Vital signs: BP 100/60, HR 85, RR 16, SpO2 96%.	ECG showed normal sinus rhythm. Chest X-ray showed infiltrates in the left lung.	Admitted to the medical ward for further observation and treatment.

Kentish Town, London NW1 9NB

Structuras	
------------	--


[illegible]

—

—

--	--





A3

[illegible]

Project title
116 St Pancras Way
Kentish Town, London NW1 9NB

Structures
David Joseph Consulting


Project manager
-

Date	Scale
10-01-13	1:100@ A3

Drawing Number	Revision
A160_102	I1



A3

[illegible]

Kentish Town, London NW1 9NB

Planning

Services

—

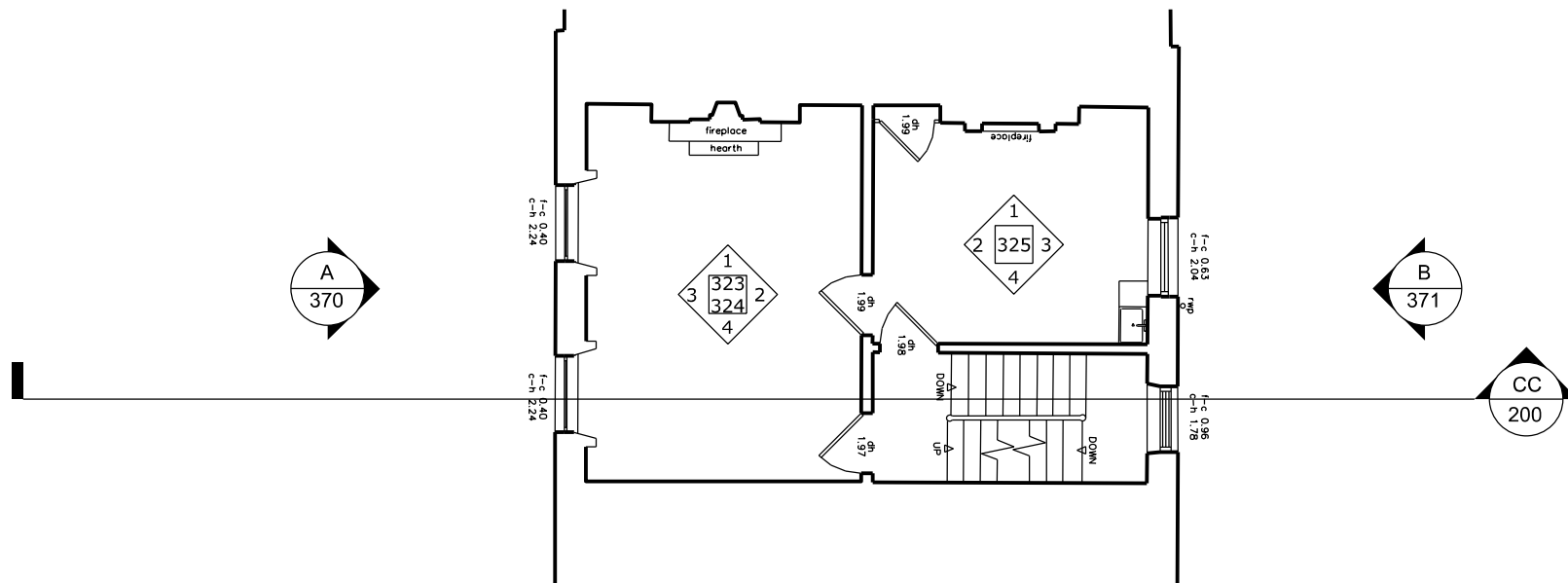
Project manager

--	--

--	--

[illegible]

--	--



A3

[illegible]

Case No.	Case Name	Case Type	Case Status	Case Date	Case Time	Case Location	Case Description	Case Notes	Case Comments
1	John Doe	Medical	Open	2023-01-01	10:00	Room 101	John Doe, 45 years old, male, presented with chest pain and shortness of breath. ECG showed ST-segment depression. Initial treatment with aspirin and nitroglycerin was administered. Patient was transferred to the cardiac catheterization lab for further evaluation.	ECG: ST-segment depression in leads II, III, aVF, and V4-V6. Troponin T: 0.05 ng/mL. Creatinine: 1.2 mg/dL. Hemoglobin: 14 g/dL. Hematocrit: 42%.	Cardiologist: Dr. Smith. Nurse: Jane Doe. Technician: John Doe.
2	Jane Smith	Medical	Closed	2023-01-02	11:00	Room 102	Jane Smith, 32 years old, female, presented with abdominal pain and nausea. Physical exam showed tenderness in the right upper quadrant. Ultrasound showed a gallstone. Patient was scheduled for laparoscopic cholecystectomy.	Ultrasound: 1.5 cm x 0.8 cm gallstone. Liver enzymes: ALT 45 U/L, AST 35 U/L, ALP 120 U/L, GGT 80 U/L. Bilirubin: 1.2 mg/dL.	Surgeon: Dr. Brown. Nurse: John Doe. Technician: Jane Smith.
3	Michael Johnson	Medical	Open	2023-01-03	12:00	Room 103	Michael Johnson, 68 years old, male, presented with weakness and fatigue. Physical exam showed pallor and tachycardia. Hemoglobin was 8 g/dL. Patient was scheduled for a blood transfusion.	Hemoglobin: 8 g/dL. Hematocrit: 24%. Iron studies: Ferritin 100 ng/mL, TIBC 450 µg/dL, Transferrin saturation 20%.	Physician: Dr. White. Nurse: Jane Doe. Technician: Michael Johnson.
4	Sarah Lee	Medical	Open	2023-01-04	13:00	Room 104	Sarah Lee, 28 years old, female, presented with a rash and joint pain. Physical exam showed a maculopapular rash on the lower extremities. Blood tests showed elevated inflammatory markers. Patient was started on corticosteroids.	ESR: 45 mm/hr. CRP: 10 mg/L. ANA: Positive. Rheumatoid factor: Negative.	Rheumatologist: Dr. Green. Nurse: John Doe. Technician: Sarah Lee.
5	David Kim	Medical	Closed	2023-01-05	14:00	Room 105	David Kim, 55 years old, male, presented with a headache and vomiting. Physical exam showed a normal neurological exam. CT scan of the head showed a small subdural hematoma. Patient was observed in the ICU.	CT scan: 1.5 cm x 1.0 cm subdural hematoma in the right parietal region. No midline shift.	Neurologist: Dr. Black. Nurse: Jane Doe. Technician: David Kim.
6	Emily White	Medical	Open	2023-01-06	15:00	Room 106	Emily White, 38 years old, female, presented with a fever and cough. Physical exam showed crackles in the lower lung fields. Chest X-ray showed consolidation in the right lower lobe. Patient was started on antibiotics.	Chest X-ray: Consolidation in the right lower lobe. Sputum culture: Positive for Streptococcus pneumoniae.	Pulmonologist: Dr. Gray. Nurse: John Doe. Technician: Emily White.
7	Robert Brown	Medical	Open	2023-01-07	16:00	Room 107	Robert Brown, 72 years old, male, presented with a fall and hip pain. Physical exam showed a tender point over the right hip. X-ray showed a fracture of the right femoral neck. Patient was scheduled for hip surgery.	X-ray: Fracture of the right femoral neck. Displacement: 3 mm.	Orthopedic Surgeon: Dr. White. Nurse: Jane Doe. Technician: Robert Brown.
8	Lisa Green	Medical	Closed	2023-01-08	17:00	Room 108	Lisa Green, 42 years old, female, presented with a rash and joint pain. Physical exam showed a maculopapular rash on the lower extremities. Blood tests showed elevated inflammatory markers. Patient was started on corticosteroids.	ESR: 45 mm/hr. CRP: 10 mg/L. ANA: Positive. Rheumatoid factor: Negative.	Rheumatologist: Dr. Black. Nurse: John Doe. Technician: Lisa Green.
9	James Wilson	Medical	Open	2023-01-09	18:00	Room 109	James Wilson, 65 years old, male, presented with a headache and vomiting. Physical exam showed a normal neurological exam. CT scan of the head showed a small subdural hematoma. Patient was observed in the ICU.	CT scan: 1.5 cm x 1.0 cm subdural hematoma in the right parietal region. No midline shift.	Neurologist: Dr. Gray. Nurse: Jane Doe. Technician: James Wilson.
10	Amanda Taylor	Medical	Open	2023-01-10	19:00	Room 110	Amanda Taylor, 35 years old, female, presented with a fever and cough. Physical exam showed crackles in the lower lung fields. Chest X-ray showed consolidation in the right lower lobe. Patient was started on antibiotics.	Chest X-ray: Consolidation in the right lower lobe. Sputum culture: Positive for Streptococcus pneumoniae.	Pulmonologist: Dr. White. Nurse: John Doe. Technician: Amanda Taylor.
11	Christopher Davis	Medical	Closed	2023-01-11	20:00	Room 111	Christopher Davis, 58 years old, male, presented with a fall and hip pain. Physical exam showed a tender point over the right hip. X-ray showed a fracture of the right femoral neck. Patient was scheduled for hip surgery.	X-ray: Fracture of the right femoral neck. Displacement: 3 mm.	Orthopedic Surgeon: Dr. Black. Nurse: Jane Doe. Technician: Christopher Davis.
12	Michelle Garcia	Medical	Open	2023-01-12	21:00	Room 112	Michelle Garcia, 48 years old, female, presented with a rash and joint pain. Physical exam showed a maculopapular rash on the lower extremities. Blood tests showed elevated inflammatory markers. Patient was started on corticosteroids.	ESR: 45 mm/hr. CRP: 10 mg/L. ANA: Positive. Rheumatoid factor: Negative.	Rheumatologist: Dr. Gray. Nurse: John Doe. Technician: Michelle Garcia.
13	Kevin Martinez	Medical	Open	2023-01-13	22:00	Room 113	Kevin Martinez, 70 years old, male, presented with a headache and vomiting. Physical exam showed a normal neurological exam. CT scan of the head showed a small subdural hematoma. Patient was observed in the ICU.	CT scan: 1.5 cm x 1.0 cm subdural hematoma in the right parietal region. No midline shift.	Neurologist: Dr. White. Nurse: Jane Doe. Technician: Kevin Martinez.
14	Stephanie Lopez	Medical	Closed	2023-01-14	23:00	Room 114	Stephanie Lopez, 30 years old, female, presented with a fever and cough. Physical exam showed crackles in the lower lung fields. Chest X-ray showed consolidation in the right lower lobe. Patient was started on antibiotics.	Chest X-ray: Consolidation in the right lower lobe. Sputum culture: Positive for Streptococcus pneumoniae.	Pulmonologist: Dr. Black. Nurse: John Doe. Technician: Stephanie Lopez.
15	Anthony Hernandez	Medical	Open	2023-01-15	00:00	Room 115	Anthony Hernandez, 60 years old, male, presented with a fall and hip pain. Physical exam showed a tender point over the right hip. X-ray showed a fracture of the right femoral neck. Patient was scheduled for hip surgery.	X-ray: Fracture of the right femoral neck. Displacement: 3 mm.	Orthopedic Surgeon: Dr. Gray. Nurse: Jane Doe. Technician: Anthony Hernandez.
16	Victoria King	Medical	Open	2023-01-16	01:00	Room 116	Victoria King, 40 years old, female, presented with a rash and joint pain. Physical exam showed a maculopapular rash on the lower extremities. Blood tests showed elevated inflammatory markers. Patient was started on corticosteroids.	ESR: 45 mm/hr. CRP: 10 mg/L. ANA: Positive. Rheumatoid factor: Negative.	Rheumatologist: Dr. White. Nurse: John Doe. Technician: Victoria King.
17	Gregory Scott	Medical	Closed	2023-01-17	02:00	Room 117	Gregory Scott, 62 years old, male, presented with a headache and vomiting. Physical exam showed a normal neurological exam. CT scan of the head showed a small subdural hematoma. Patient was observed in the ICU.	CT scan: 1.5 cm x 1.0 cm subdural hematoma in the right parietal region. No midline shift.	Neurologist: Dr. Black. Nurse: Jane Doe. Technician: Gregory Scott.
18	Christina Adams	Medical	Open	2023-01-18	03:00	Room 118	Christina Adams, 33 years old, female, presented with a fever and cough. Physical exam showed crackles in the lower lung fields. Chest X-ray showed consolidation in the right lower lobe. Patient was started on antibiotics.	Chest X-ray: Consolidation in the right lower lobe. Sputum culture: Positive for Streptococcus pneumoniae.	Pulmonologist: Dr. Gray. Nurse: John Doe. Technician: Christina Adams.
19	Timothy Baker	Medical	Open	2023-01-19	04:00	Room 119	Timothy Baker, 75 years old, male, presented with a fall and hip pain. Physical exam showed a tender point over the right hip. X-ray showed a fracture of the right femoral neck. Patient		
20	Natalie Nelson	Medical	Closed	2023-01-20	05:00	Room 120	Natalie Nelson, 45 years old, female, presented with a rash and joint pain. Physical exam showed a maculopapular rash on the lower extremities. Blood tests showed elevated inflammatory markers. Patient was started on corticosteroids.	ESR: 45 mm/hr. CRP: 10 mg/L. ANA: Positive. Rheumatoid factor: Negative.	Rheumatologist: Dr. Black. Nurse: John Doe. Technician: Natalie Nelson.
21	Jonathan Phillips	Medical	Open	2023-01-21	06:00	Room 121	Jonathan Phillips, 67 years old, male, presented with a headache and vomiting. Physical exam showed a normal neurological exam. CT scan of the head showed a small subdural hematoma. Patient was observed in the ICU.	CT scan: 1.5 cm x 1.0 cm subdural hematoma in the right parietal region. No midline shift.	Neurologist: Dr. Gray. Nurse: Jane Doe. Technician: Jonathan Phillips.
22	Kimberly Campbell	Medical	Closed	2023-01-22	07:00	Room 122	Kimberly Campbell, 37 years old, female, presented with a fever and cough. Physical exam showed crackles in the lower lung fields. Chest X-ray showed consolidation in the right lower lobe. Patient was started on antibiotics.	Chest X-ray: Consolidation in the right lower lobe. Sputum culture: Positive for Streptococcus pneumoniae.	Pulmonologist: Dr. White. Nurse: John Doe. Technician: Kimberly Campbell.
23	Benjamin Evans	Medical	Open	2023-01-23	08:00	Room 123	Benjamin Evans, 73 years old, male, presented with a fall and hip pain. Physical exam showed a tender point over the right hip. X-ray showed a fracture of the right femoral neck. Patient		

Project title
116 St Pancras Way
Kentish Town, London NW1 9NB

Structures
David Joseph Consulting

Project manager	
-	

Date	Scale
10-01-13	1:100@ A3

Drawing Number	Revision
A160_104	I1



Clive Sall Architecture Ltd.
Unit 2, Providence Yard,
Ezra Street, London, E2 7RJ



Clive Sall Architecture Ltd.
Unit 2, Providence Yard,
Ezra Street, London, E2 7RJ

A3

[illegible]

Project title
116 St Pancras Way
Kentish Town, London NW1 9NB

Structures
David Joseph Consulting

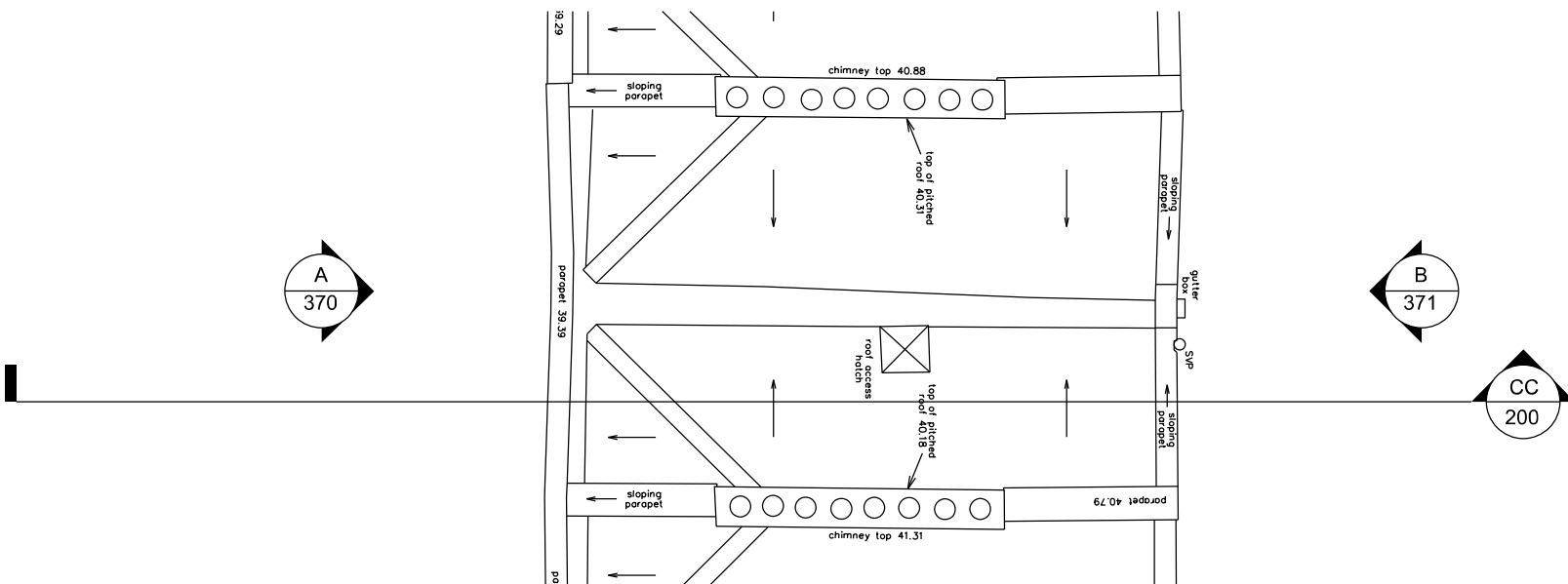
Project manager	
-	

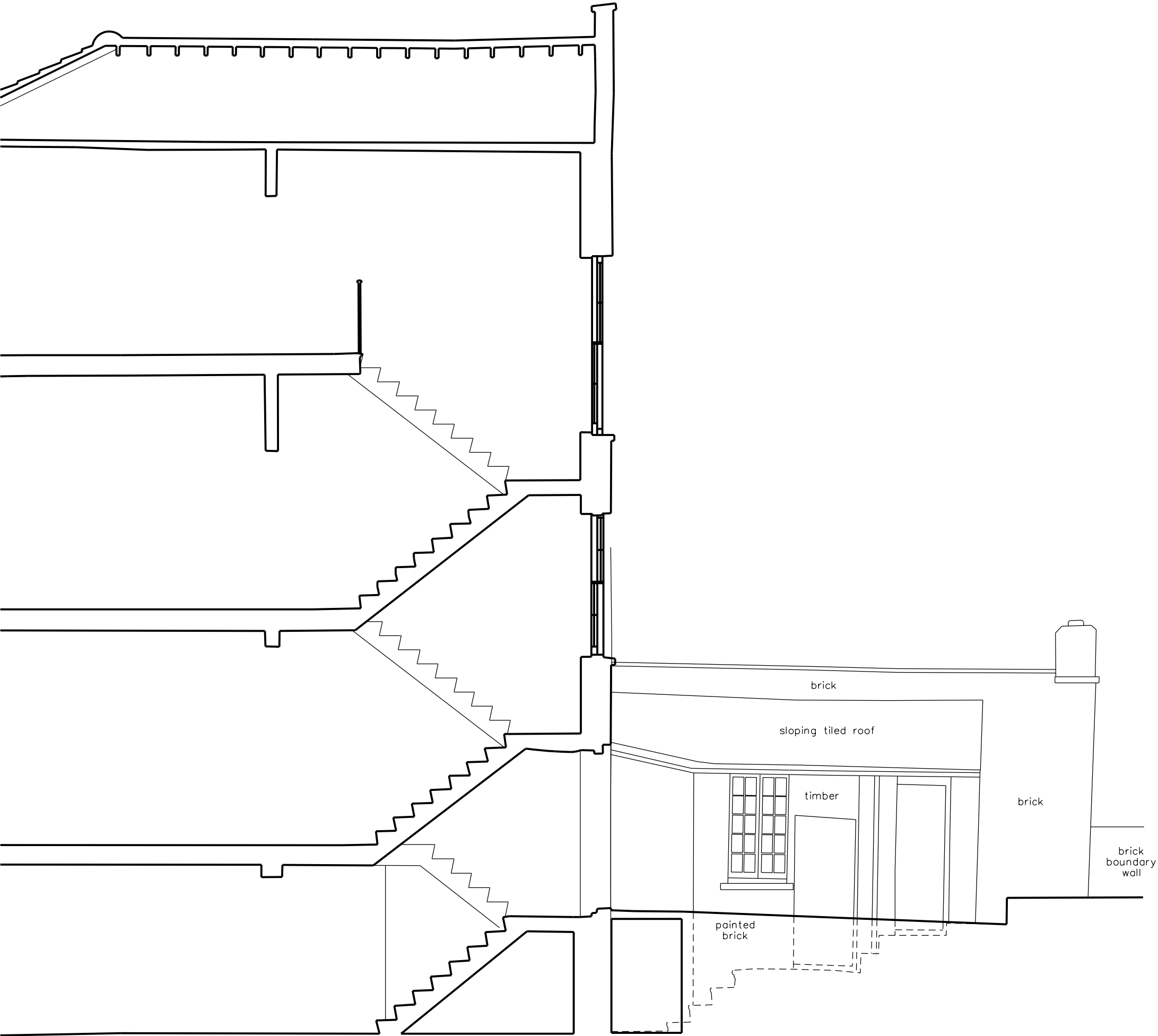
Date	Scale
10-01-13	1:100@ A3

Drawing Number	Revision
A160_105	I1



Clive Sall Architecture Ltd.
Unit 2, Providence Yard,
Ezra Street, London, E2 7RJ






DO NOT SCALE FROM THIS DRAWING

Contractor to check and verify all dimensions on site prior to commencing work.

Any discrepancies to be reported to the architect immediately.

This drawing is copyrighted



A3

REVISIONS		
No:	Date	Description



Client

Philip Herrey

Project title

116 St Pancras Way

Kentish Town, London NW1 9NB

Status

Feasibility

Structures

David Joseph Consulting

Services

-

Project manager

-

Drawing Title

Existing
Long Section CC

Date

14-01-13

Scale

1:50@ A3

Drawn

-

Checked

-

Authorised

-

Drawing Number

A160_200

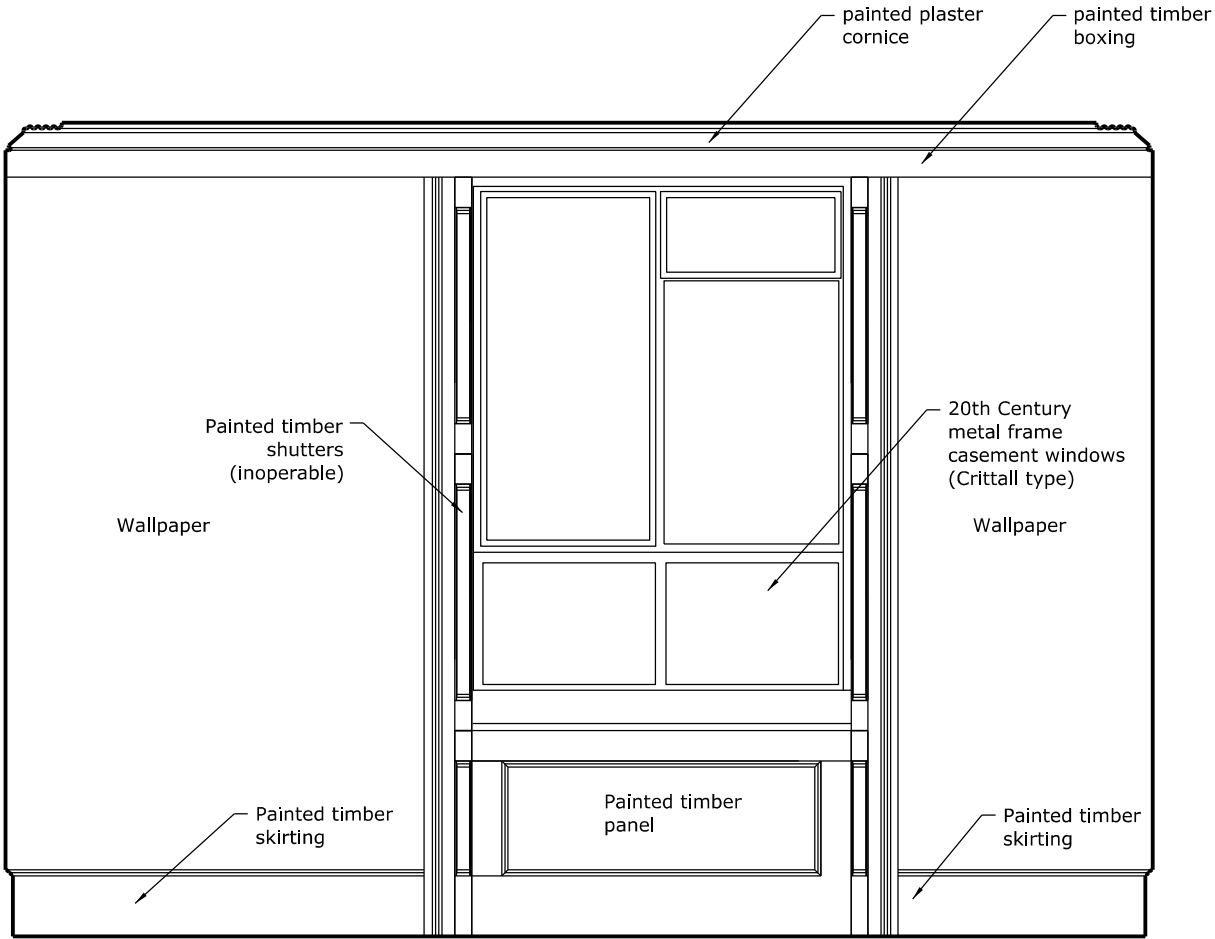
Revision

I1

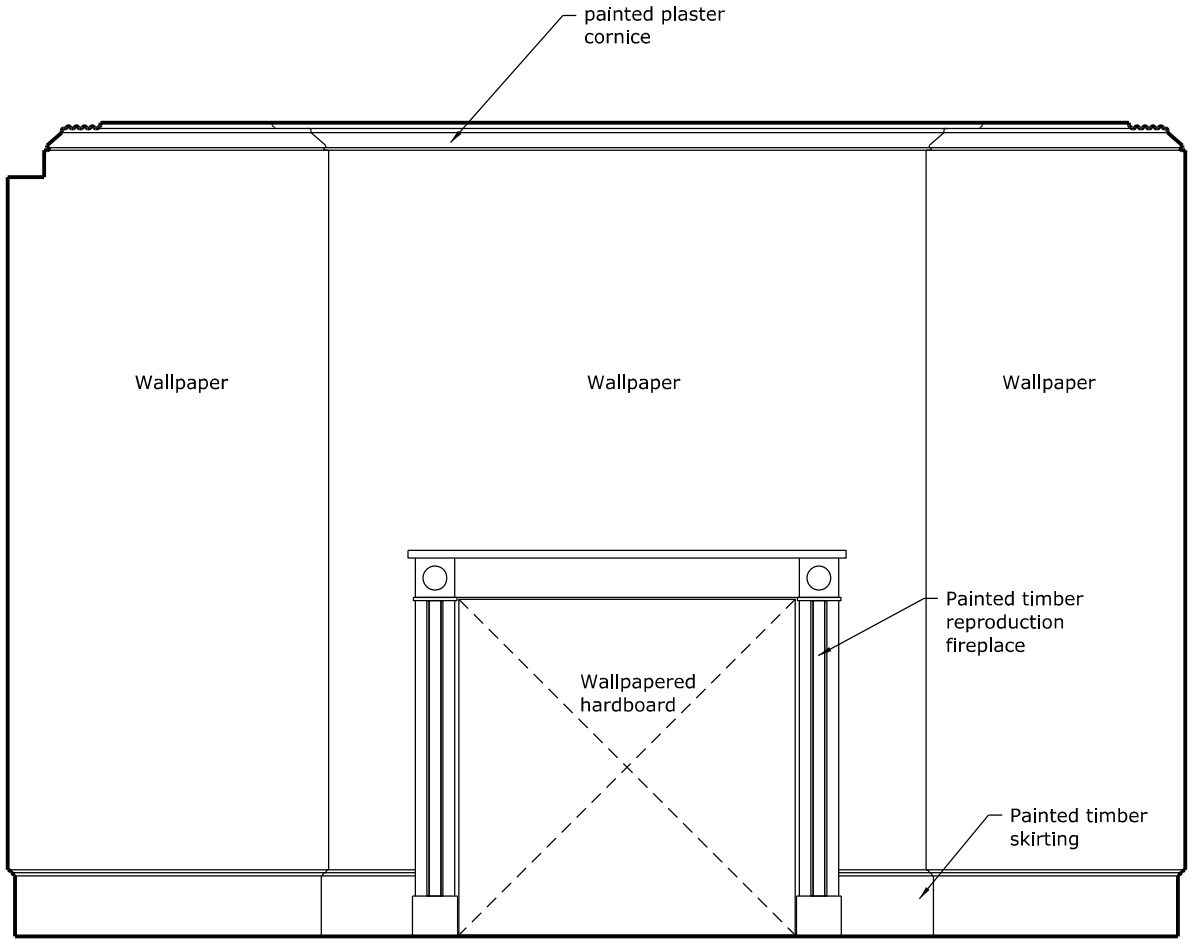
Copyright CLIVE SALL ARCHITECTURE LTD



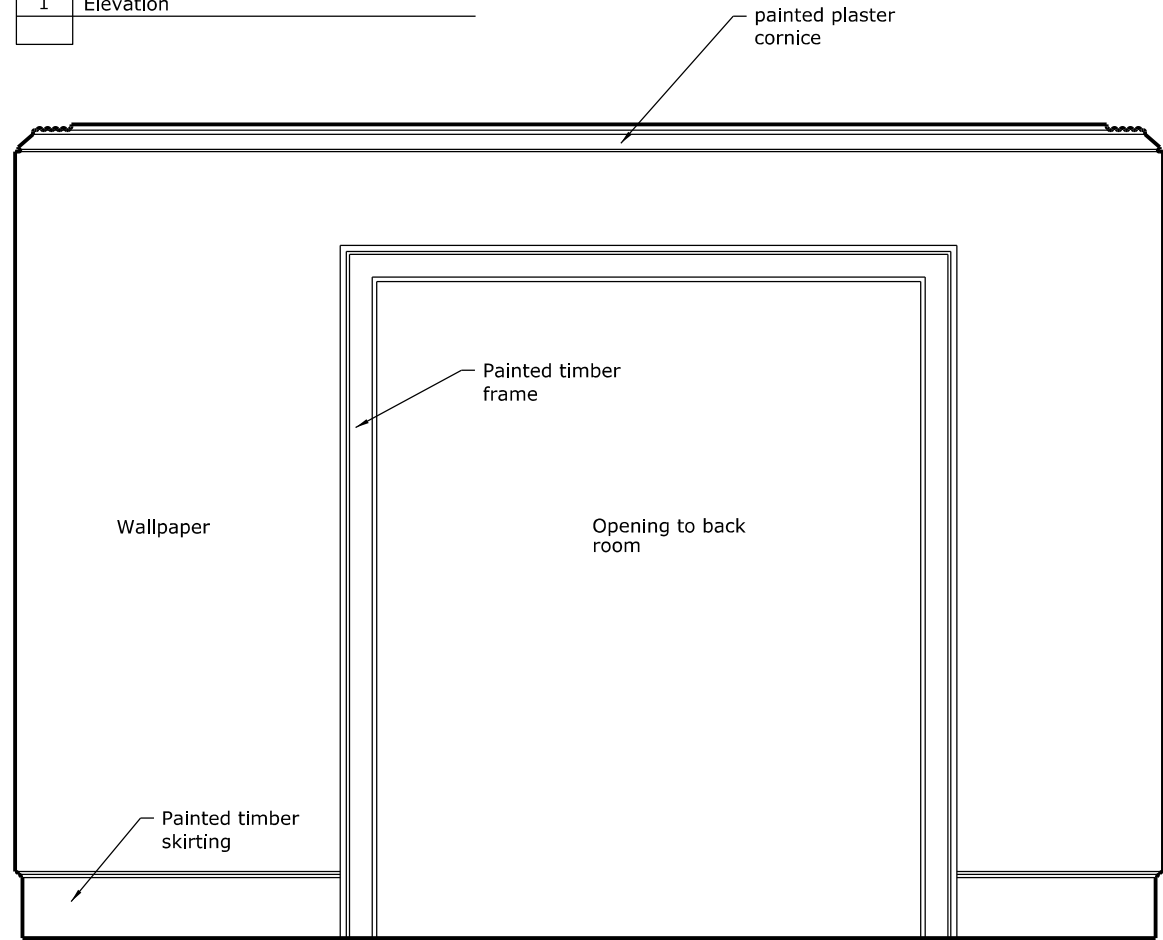
Clive Sall Architecture Ltd.
Unit 2, Providence Yard,
Ezra Street, London, E2 7RJ



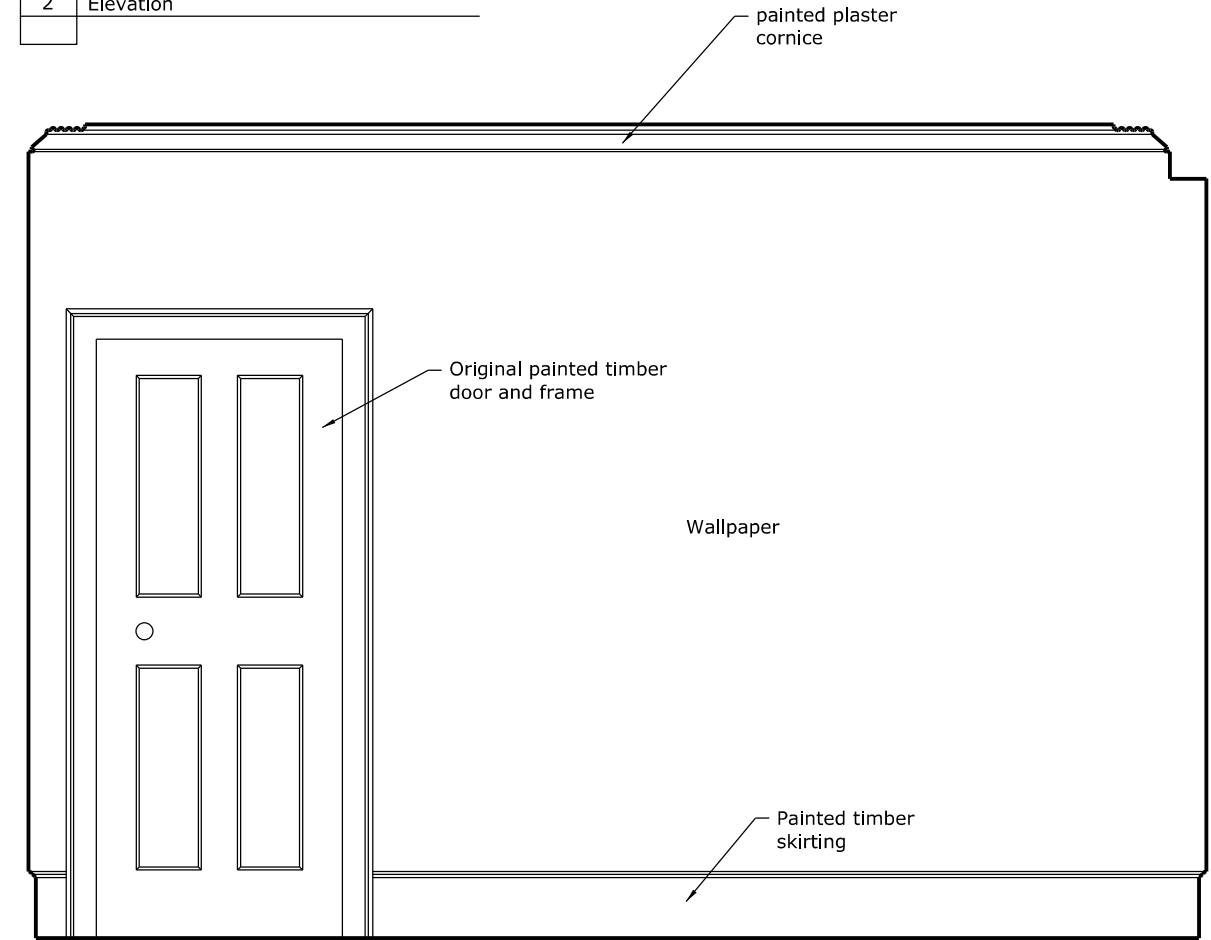
1 Elevation



2 Elevation

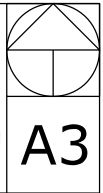


3 Elevation



4 Elevation

DO NOT SCALE FROM THIS DRAWING
Contractor to check and verify all dimensions on site prior to commencing work.
Any discrepancies to be reported to the architect immediately.
This drawing is copyrighted



REVISIONS		
No:	Date	Description

Client
Philip Herrey

Project title
116 St Pancras Way
Kentish Town, London NW1 9NB

Status
Feasibility

Structures
David Joseph Consulting

Services

Project manager

Drawing Title
Front Ground Floor Existing Elevation

Date 14-01-13	Scale 1:25@ A3	
Drawn -	Checked -	Authorised -
Drawing Number A160_321	Revision I1	



Copyright CLIVE SALL ARCHITECTURE LTD

Clive Sall Architecture Ltd.
Unit 2, Providence Yard,
Ezra Street, London, E2 7RJ

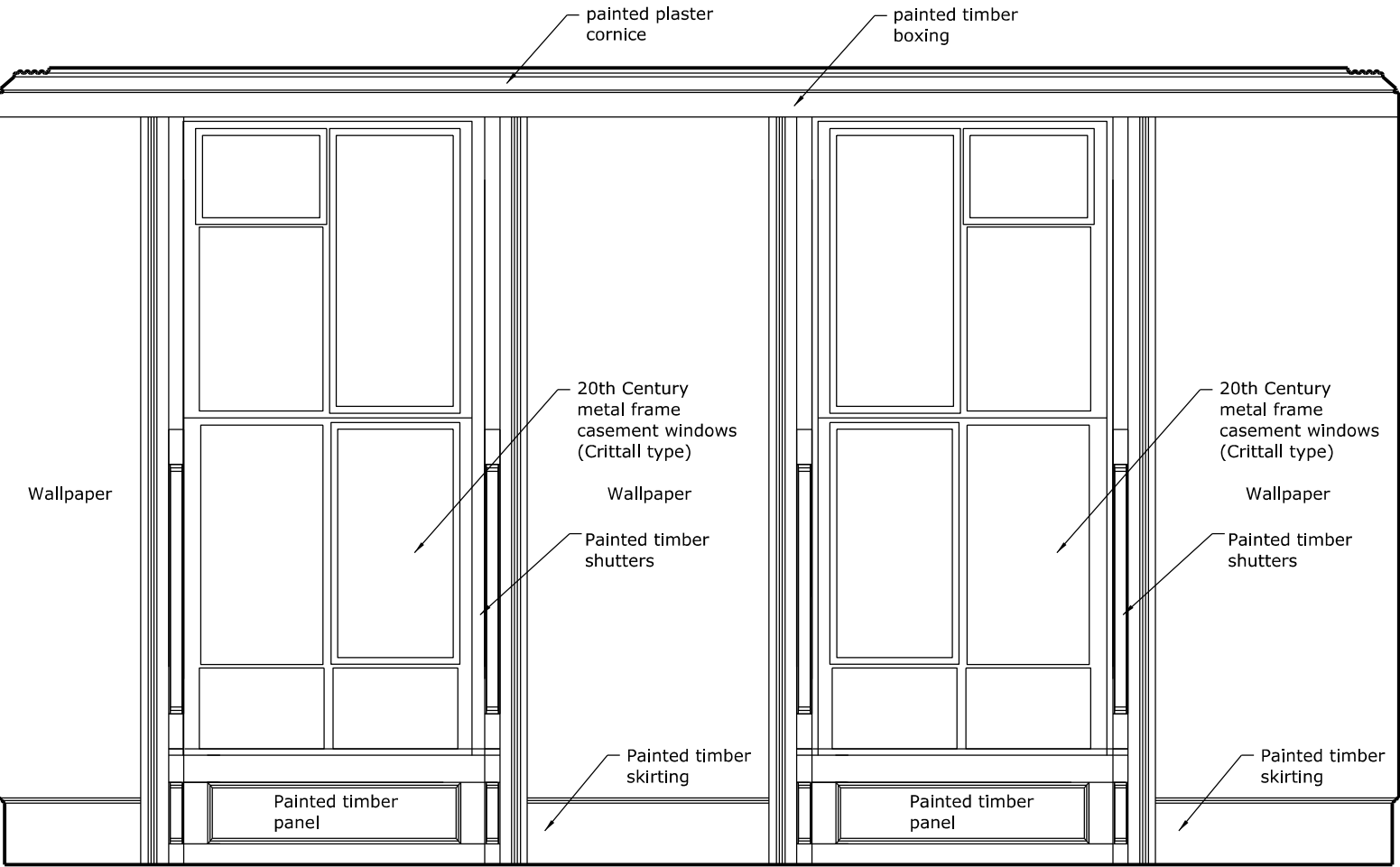


A3

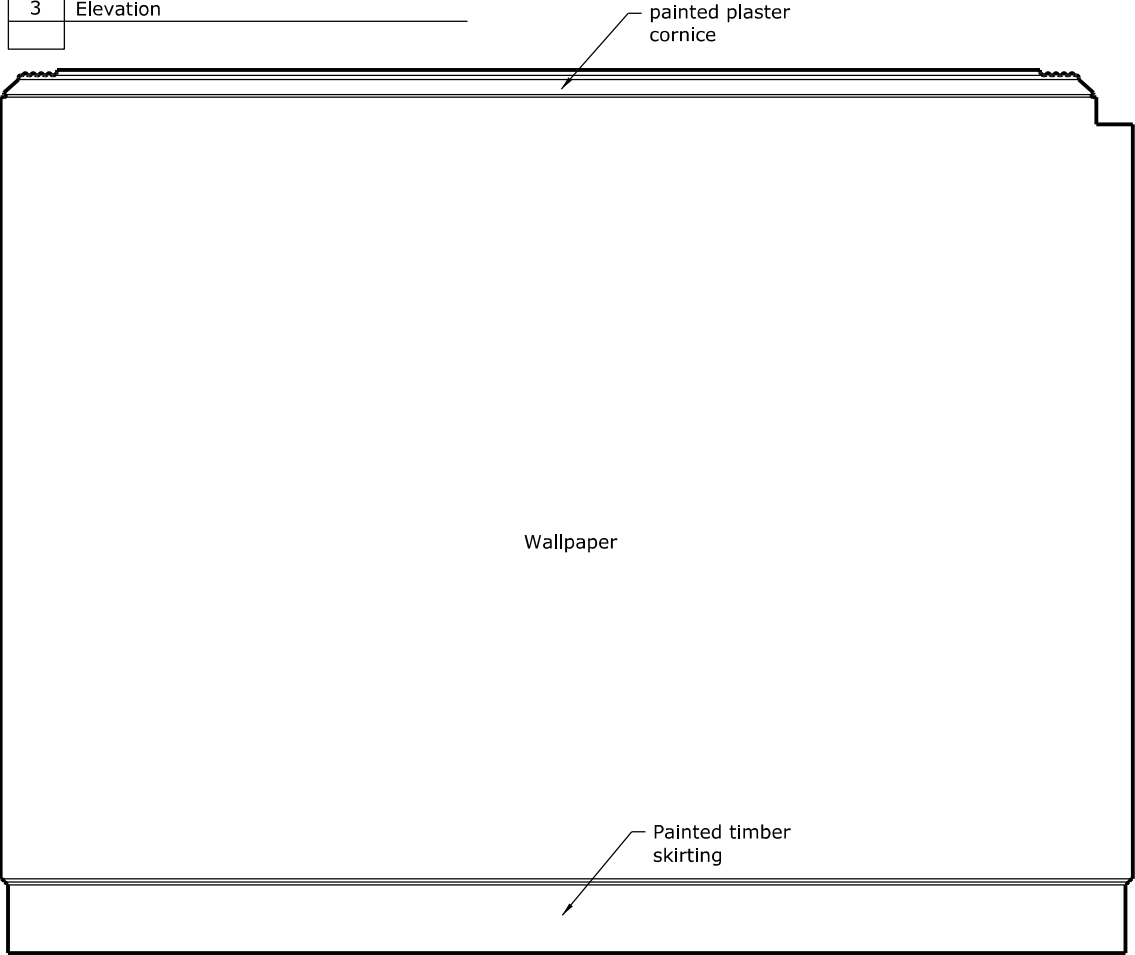
REVISIONS

[illegible]

Clive Sall Architecture Ltd.
Unit 2, Providence Yard,
Ezra Street, London, E2 7RJ



3 Elevation




4 Elevation

DO NOT SCALE FROM THIS DRAWING
Contractor to check and verify all dimensions on site prior to commencing work.
Any discrepancies to be reported to the architect immediately.
This drawing is copyrighted

A3

REVISIONS		
No:	Date	Description



Client
Philip Herrey

Project title

116 St Pancras Way
Kentish Town, London NW1 9NB

Status

Feasibility

Structures

David Joseph Consulting

Services

Project manager

Drawing Title

**Rear Ground Floor
Existing Elevation**

Date

14-01-13

Scale

1:25@ A3

Drawn

-

Checked

-

Authorised

-

Drawing Number

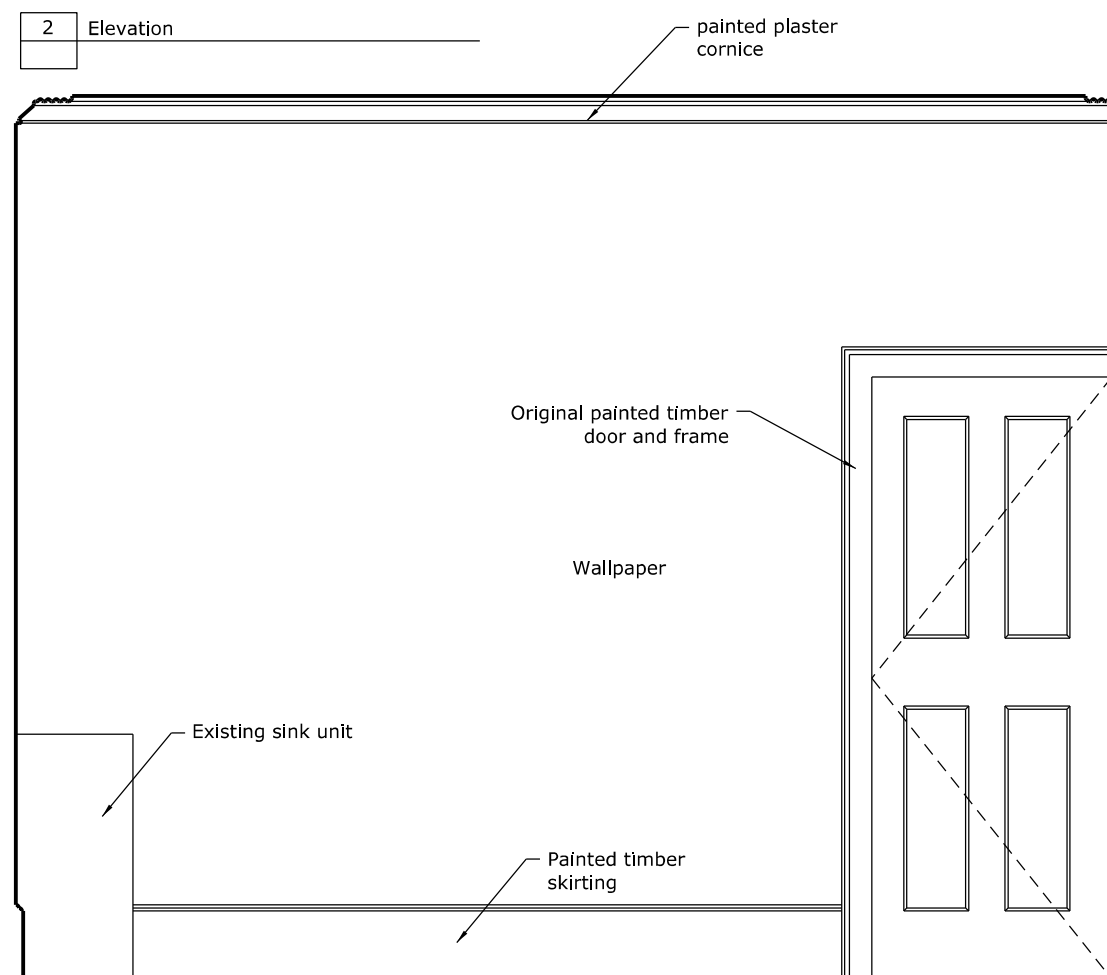
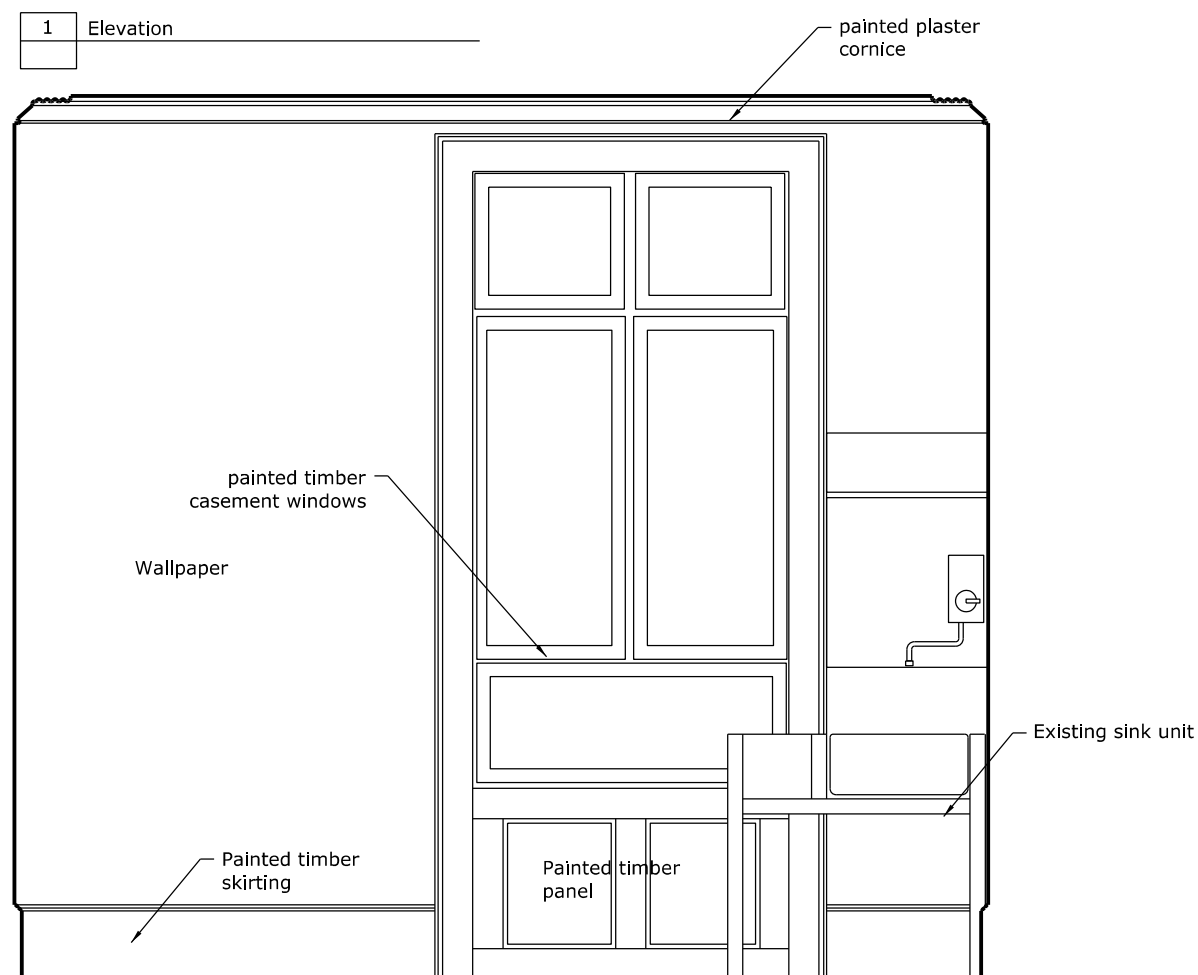
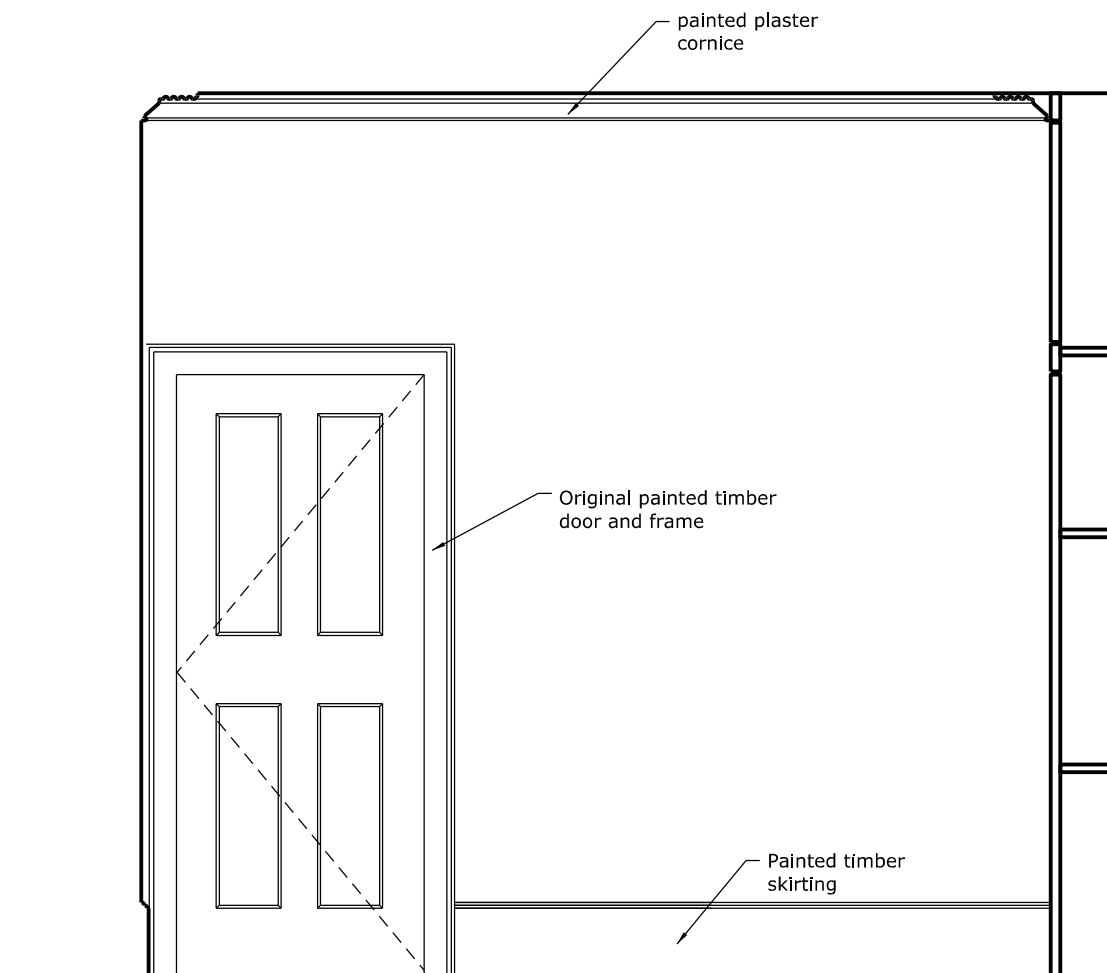
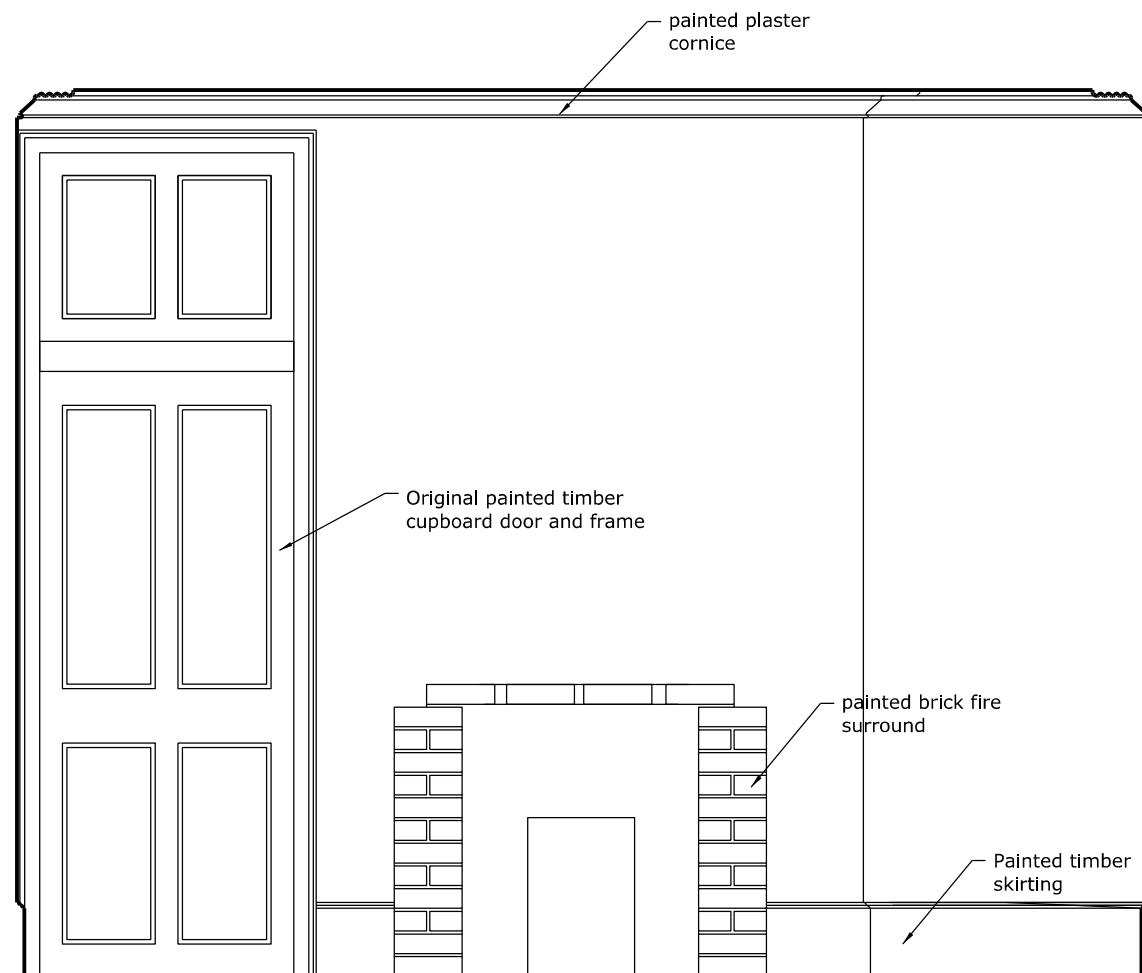
A160_324

Revision

P1

Copyright CLIVE SALL ARCHITECTURE LTD

Clive Sall Architecture Ltd.
Unit 2, Providence Yard,
Ezra Street, London, E2 7RJ



DO NOT SCALE FROM THIS DRAWING
Contractor to check and verify all dimensions on site prior to commencing work.
Any discrepancies to be reported to the architect immediately.
This drawing is copyrighted



A3

REVISIONS

[illegible]

Client
Philip Herrey

Project title
116 St Pancras Way
Kensington, London NW1 9NB

Status	Feasibility
--------	-------------

Structures
David Joseph Consulting

Services

Project manager

Drawing Title

Rear First Floor
Existing Elevation

Date	Scale
14-01-13	1:25@ A3

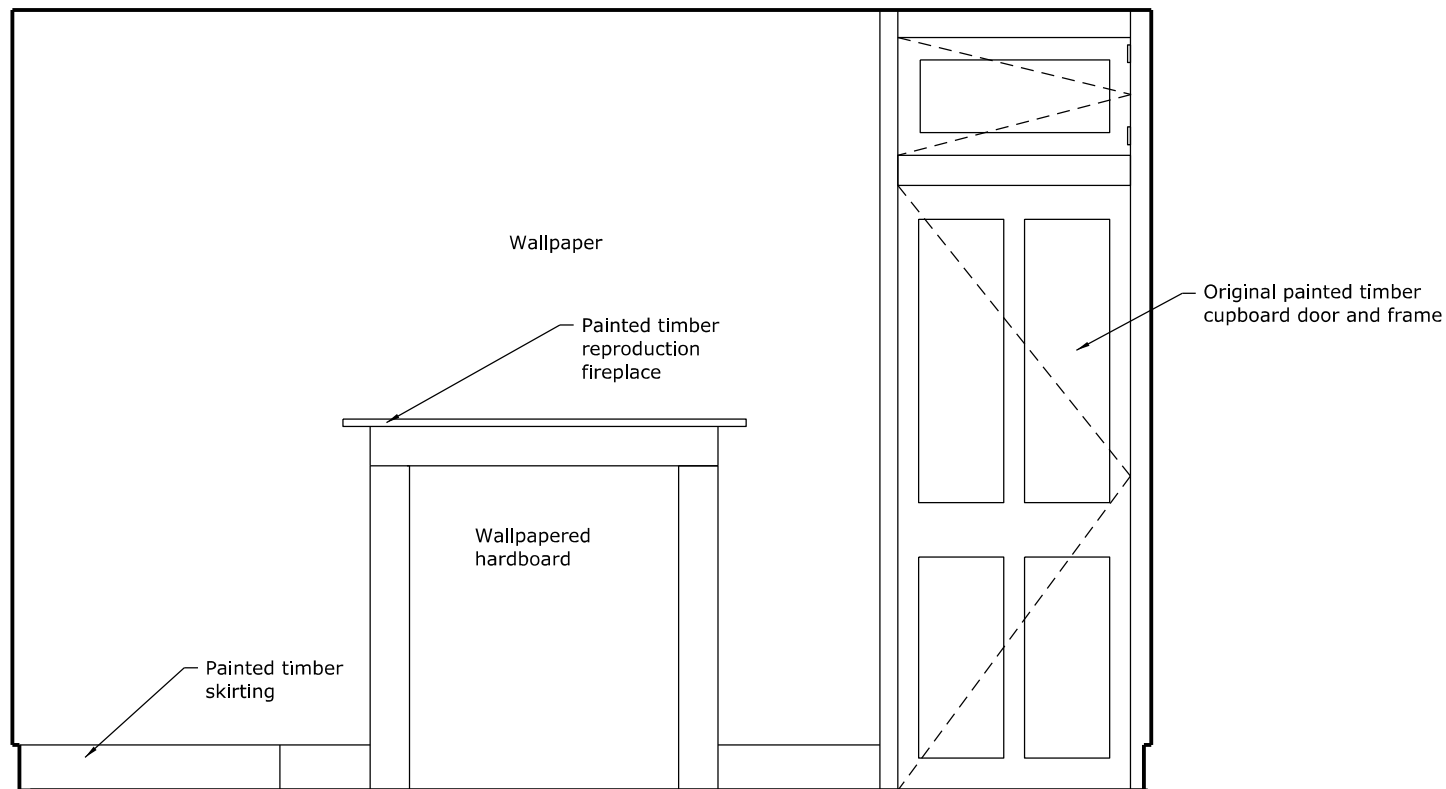
Drawn	Checked	Authorised
-	-	-

Drawing Number	Revision
A160_325	P1

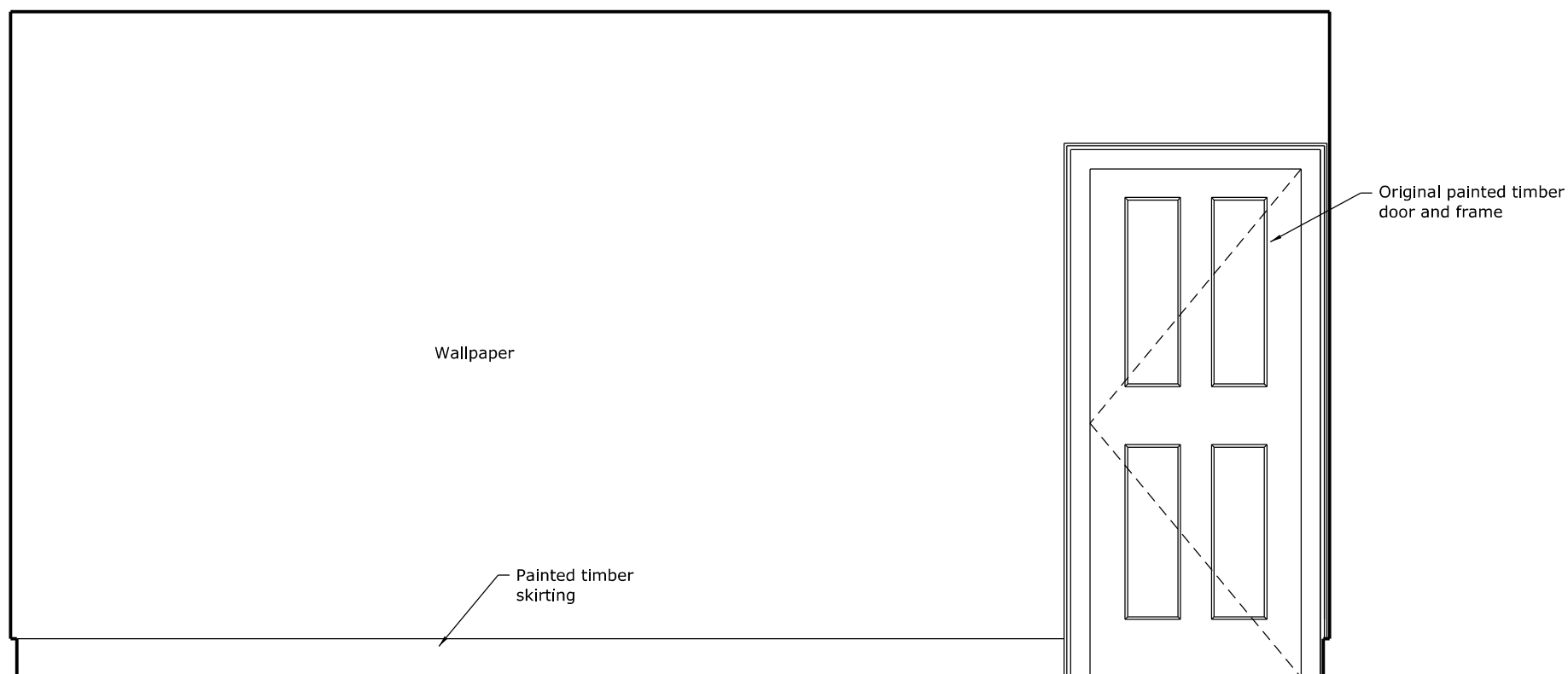
Copyright CLIVE SALL ARCHITECTURE LTD




Clive Sall Architecture Ltd.
Unit 2, Providence Yard,
Ezra Street, London, E2 7RJ



1	Elevation



2	Elevation

<p>DO NOT SCALE FROM THIS DRAWING</p> <p>Contractor to check and verify all dimensions on site prior to commencing work.</p> <p>Any discrepancies to be reported to the architect immediately.</p> <p>This drawing is copyrighted</p>	
<p></p>	<p>A3</p>

[illegible]

Client
Philip Herrey

Project title
116 St Pancras Way
Kentish Town, London NW1 9NB

Status	
--------	--

Feasibility

David Joseph Consulting

Project manager

Drawing Title
**Front Second Floor
Existing Elevation**

Date	Scale
14-01-13	1:25@ A3

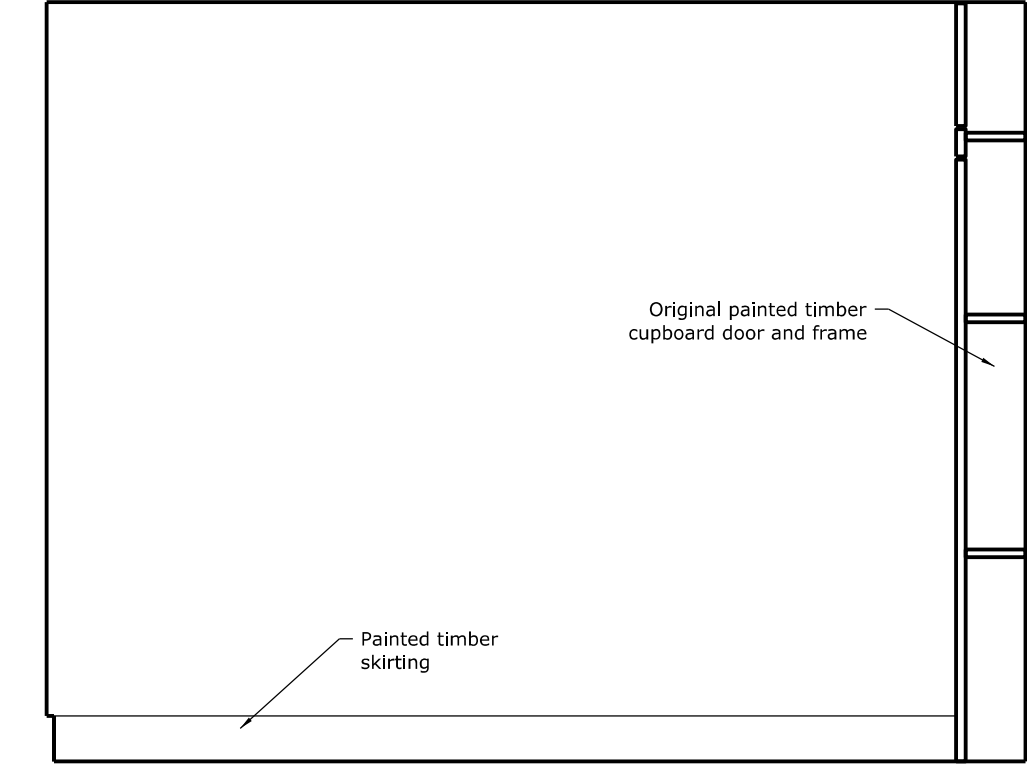
Drawn	Checked	Authorised
-	-	-

Drawing Number	Revision
A160_326	P1

Copyright CLIVE SALL ARCHITECTURE LTD

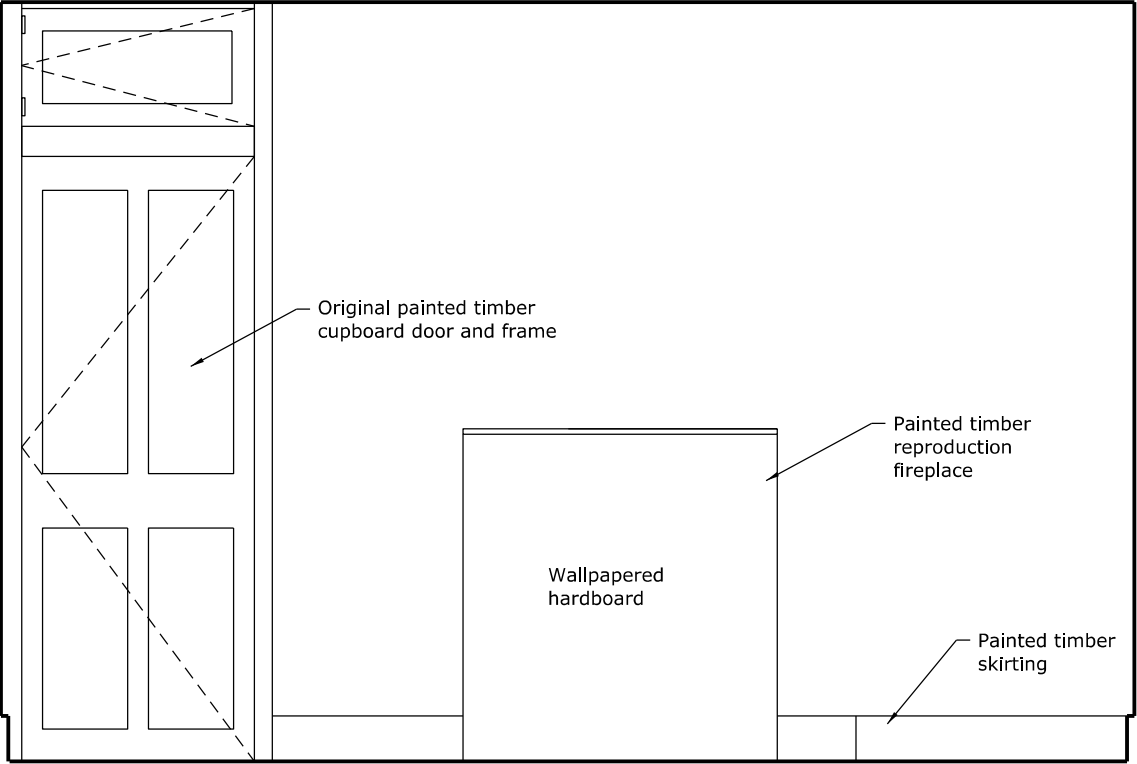


Clive Sall Architecture Ltd.
Unit 2, Providence Yard,
Ezra Street, London, E2 7RJ



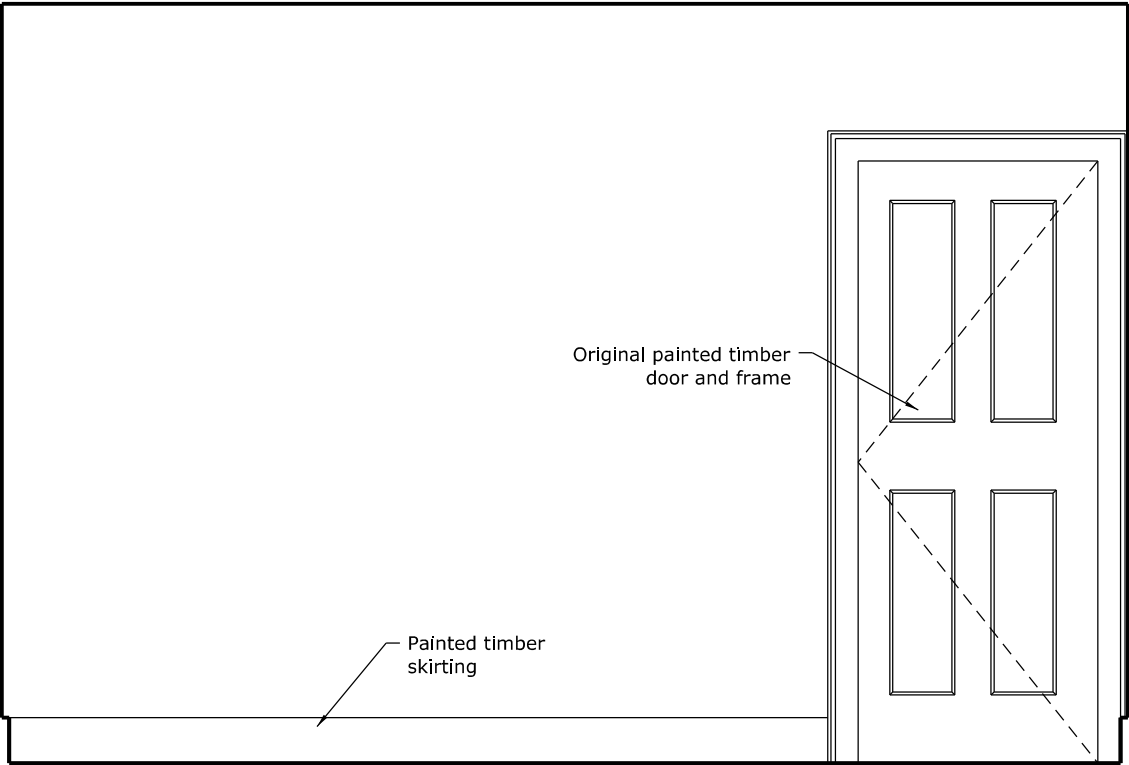
1

Elevation



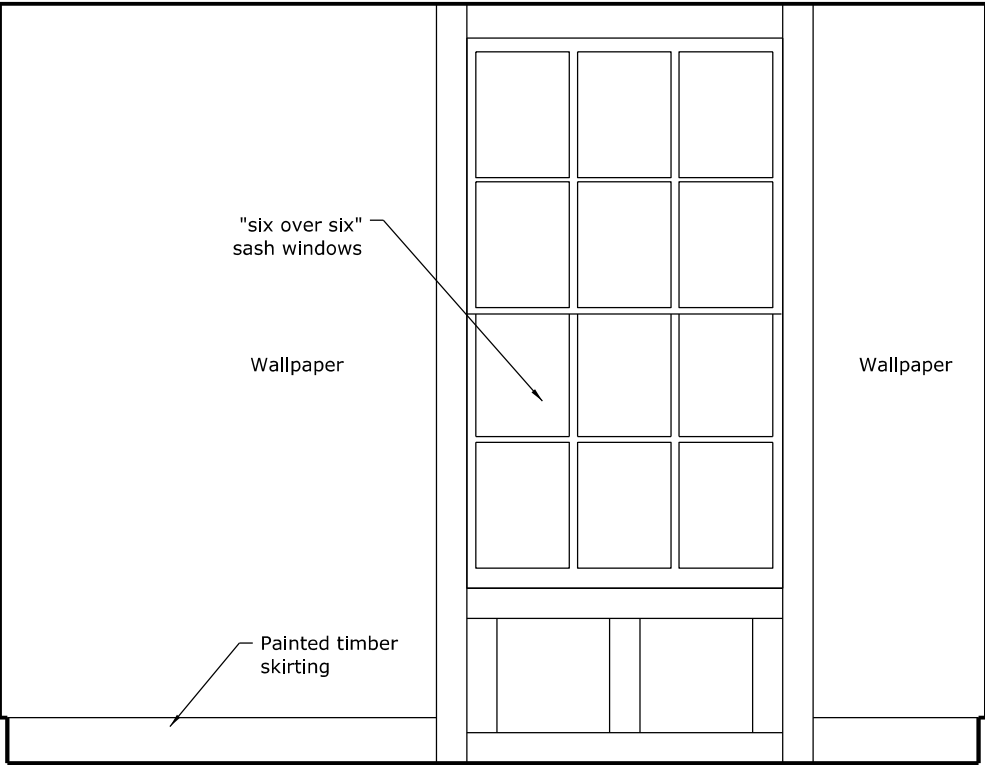
2

Elevation



3

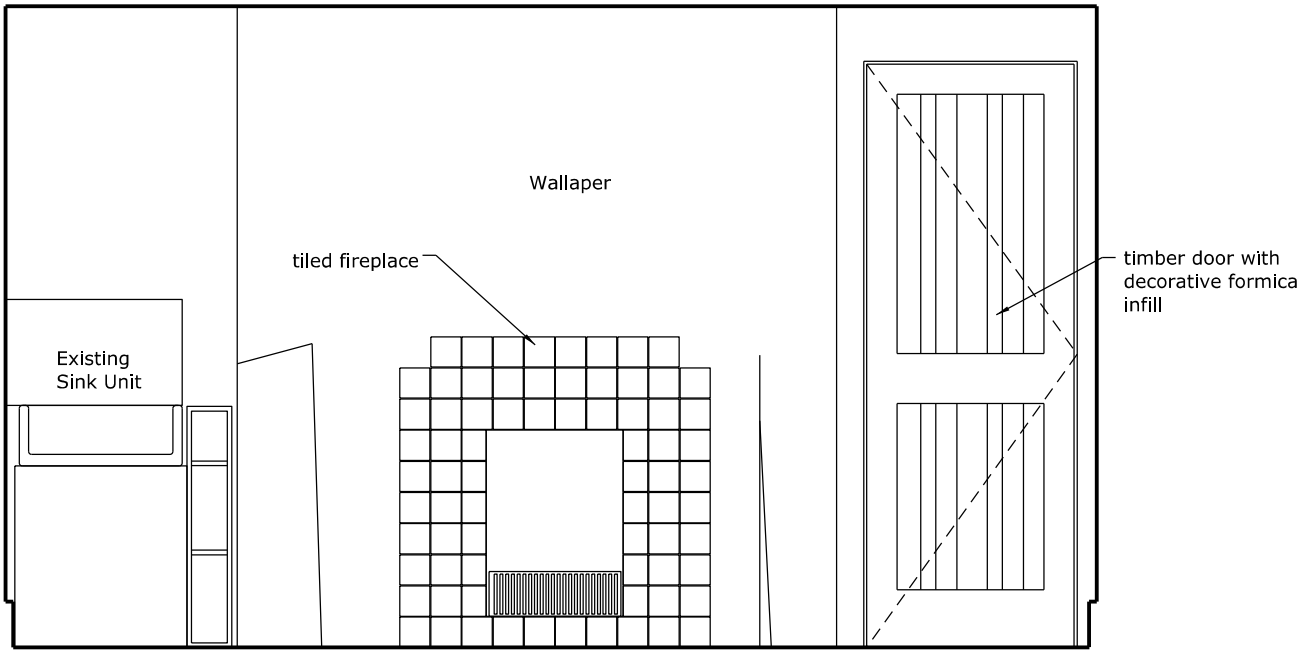
Elevation




4

Elevation

REVISIONS		
No:	Date	Description




1	Elevation



2	Elevation

DO NOT SCALE FROM THIS DRAWING
Contractor to check and verify all dimensions on site prior to commencing work.
Any discrepancies to be reported to the architect immediately.
This drawing is copyrighted



A3

REVISIONS		
No:	Date	Description

Client

Philip Herrey

Project title

116 St Pancras Way

Kentish Town, London NW1 9NB

Status

Feasibility

Structures

David Joseph Consulting

Services

Project manager

Drawing Title

Front Second Floor Existing Elevation

Date

14-01-13

Scale

1:25@ A3

Drawn

-

Checked

-

Authorised

-


Drawing Number

A160_329

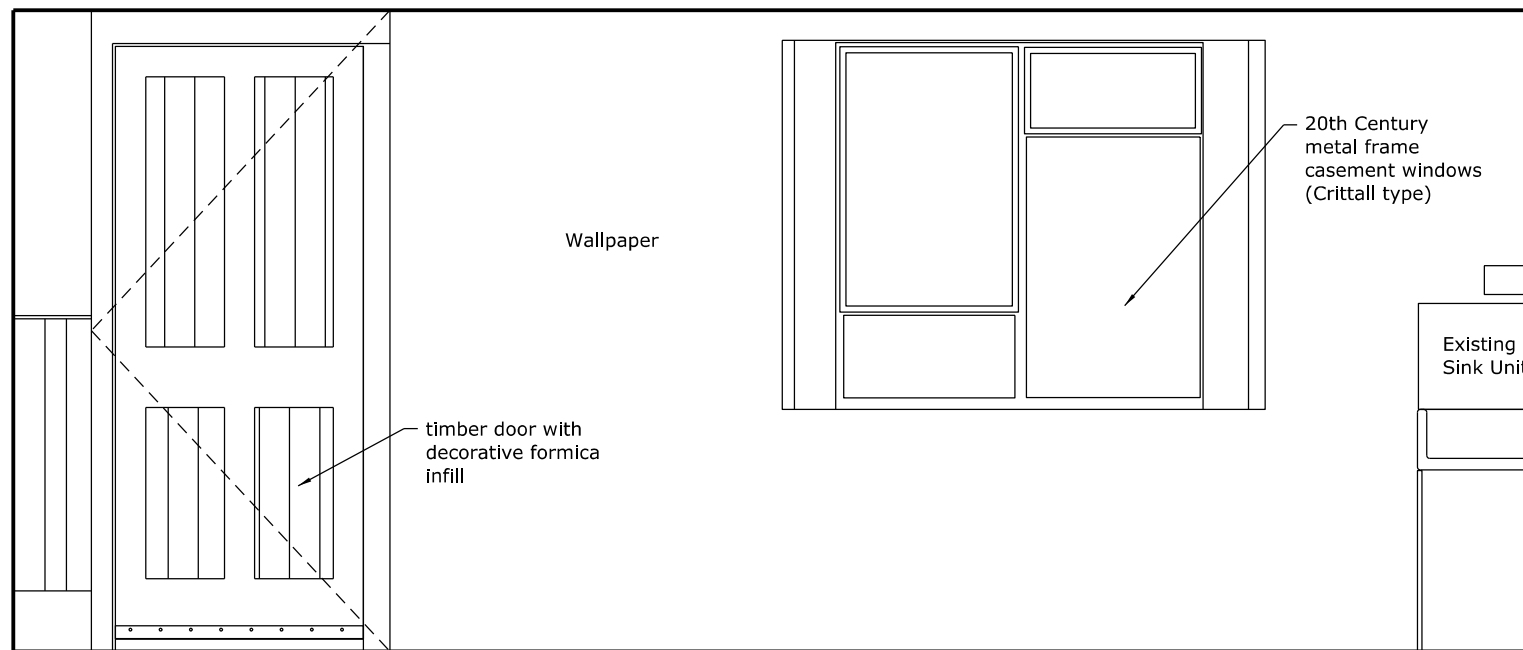
Revision

P1

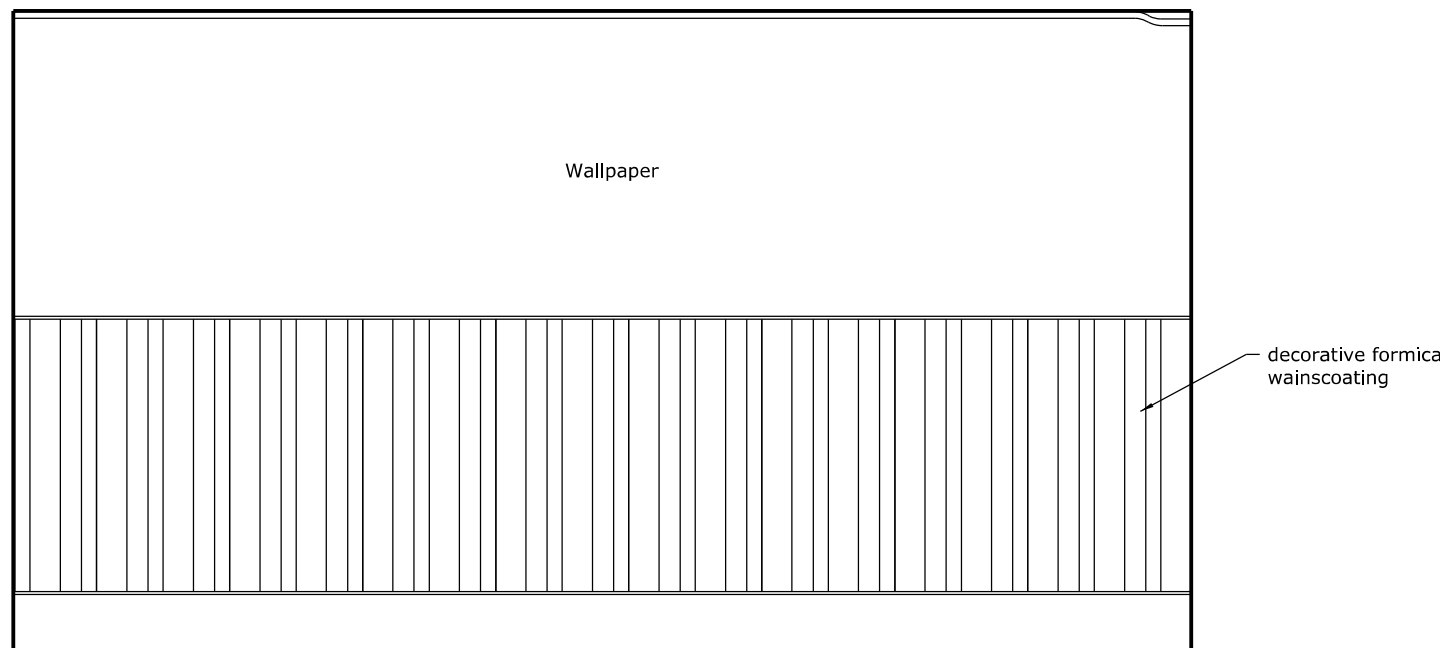
Copyright CLIVE SALL ARCHITECTURE LTD




Clive Sall Architecture Ltd.
Unit 2, Providence Yard,
Ezra Street, London, E2 7RJ



3	Elevation




4	Elevation

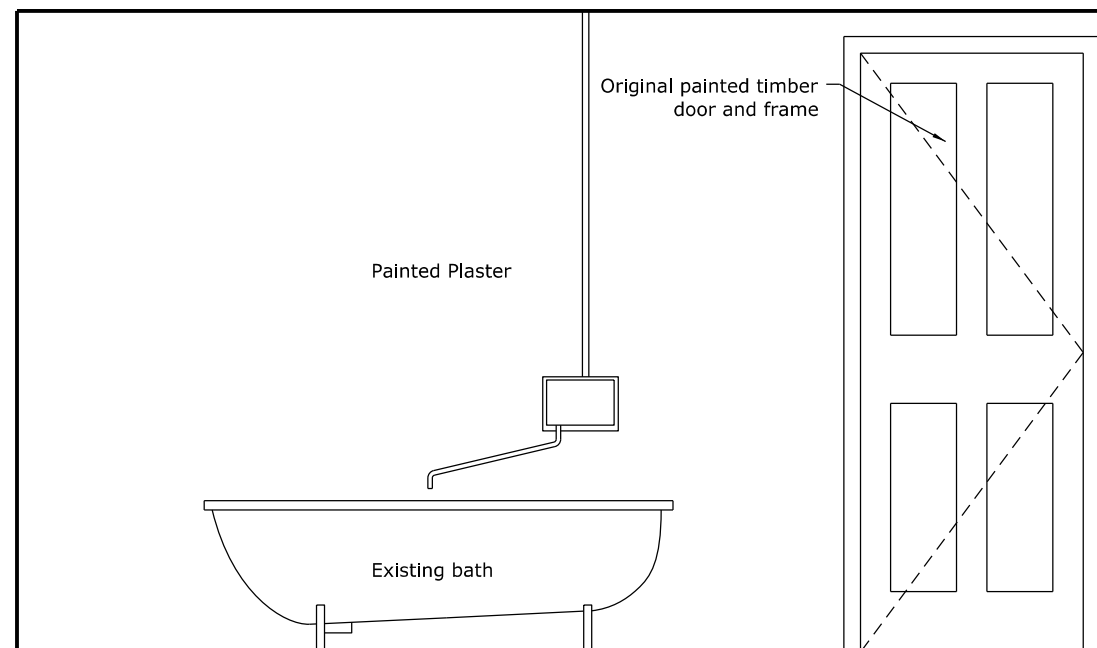
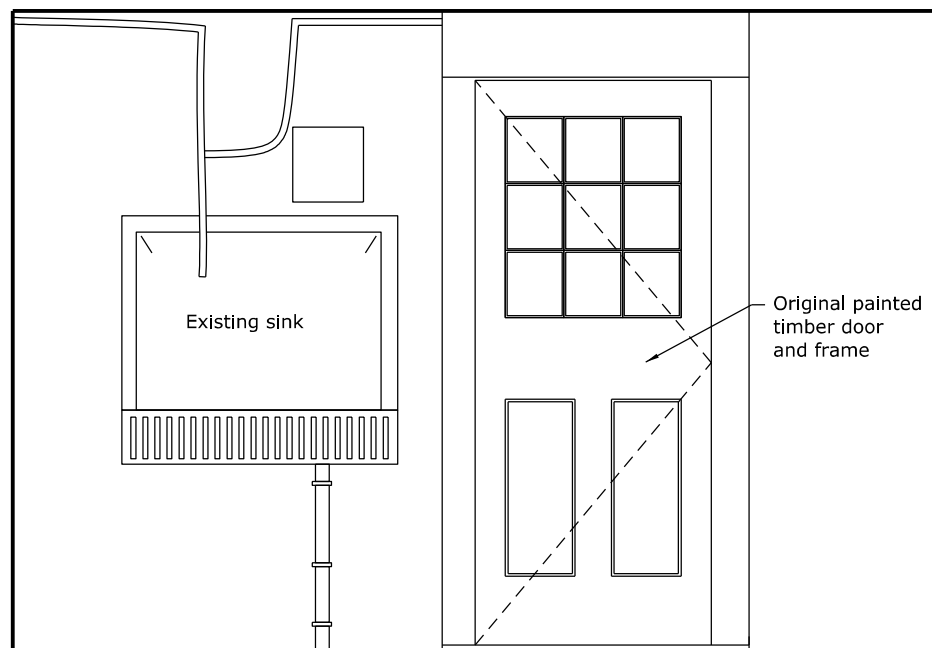
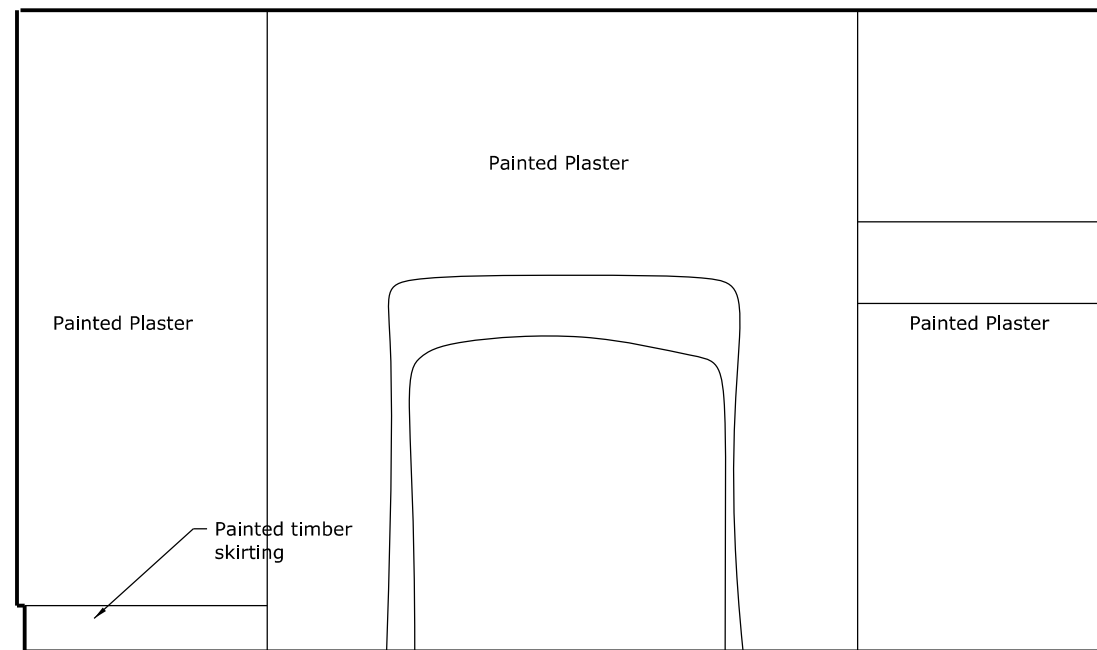
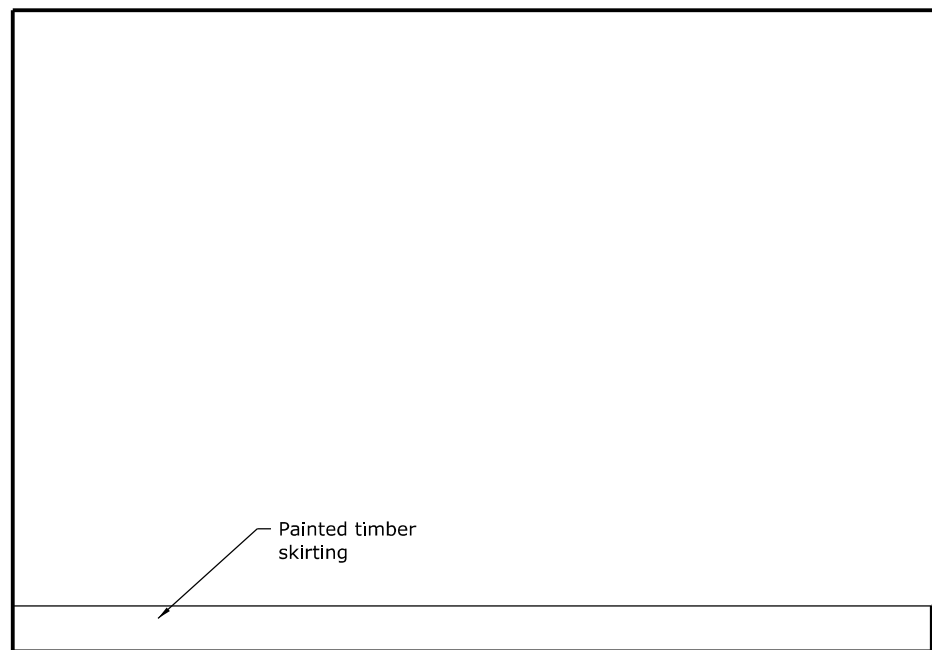
<p>DO NOT SCALE FROM THIS DRAWING</p> <p>Contractor to check and verify all dimensions on site prior to commencing work.</p> <p>Any discrepancies to be reported to the architect immediately.</p> <p>This drawing is copyrighted</p>	
<p></p>	<p>A3</p>



A3


[illegible][illegible]

Client Philip Herrey		
Project title 116 St Pancras Way Kentish Town, London NW1 9NB		
Status Feasibility		
Structures David Joseph Consulting		
Services		
Project manager		
Drawing Title Front Second Floor Existing Elevation		
Date 14-01-13	Scale 1:25@ A3	
Drawn -	Checked -	Authorised -
Drawing Number A160_330		Revision P1
Copyright CLIVE SALL ARCHITECTURE LTD		
 <p>Clive Sall Architecture Ltd. Unit 2, Providence Yard, Ezra Street, London, E2 7RJ</p>		



**DO NOT SCALE FROM
THIS DRAWING**
Contractor to check and
verify all dimensions on
site prior to commencing
work.
Any discrepancies to be reported
to the architect immediately.
This drawing is copyrighted

[illegible]

Client Philip Herrey		
Project title 116 St Pancras Way Kentish Town, London NW1 9NB		
Status Feasibility		
Structures David Joseph Consulting		
Services		
Project manager		
Drawing Title Rear Basement Level Existing Elevation		
Date 14-01-13		Scale 1:25@ A3
Drawn -	Checked -	Authorised -
Drawing Number A160_331		Revision P1
Copyright CLIVE SALL ARCHITECTURE LTD		
 Clive Sall Architecture Ltd. Unit 2, Providence Yard, Ezra Street, London, E2 7RJ		

[illegible]

Client	Philip Herrey
Project title	116 St Pancras Way Kenthsh Town, London NW1 9NB
Status	Feasibility
Structures	David Joseph Consulting
Services	
Project manager	

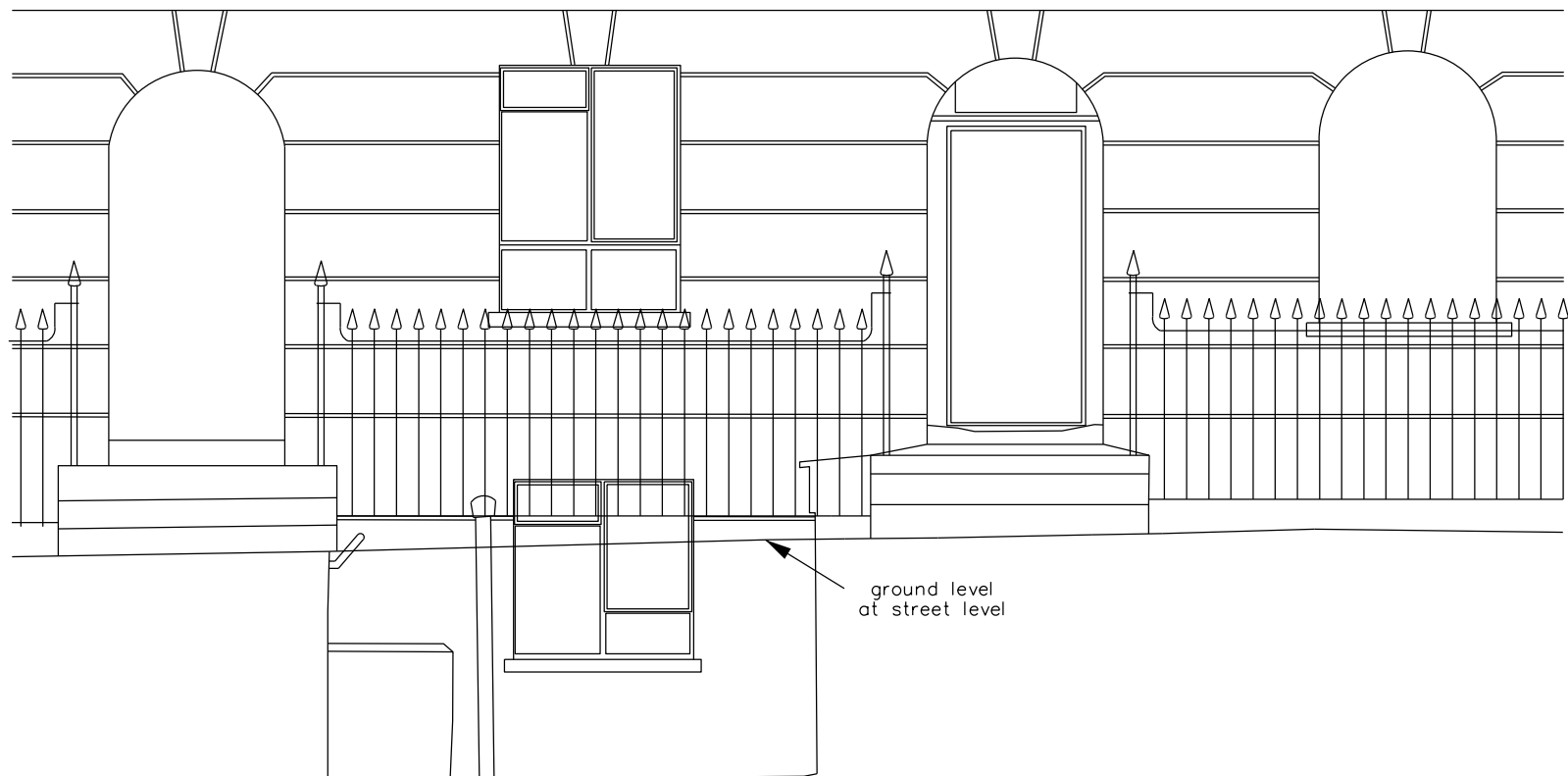
Date	Scale
14-01-13	1:25@ A3

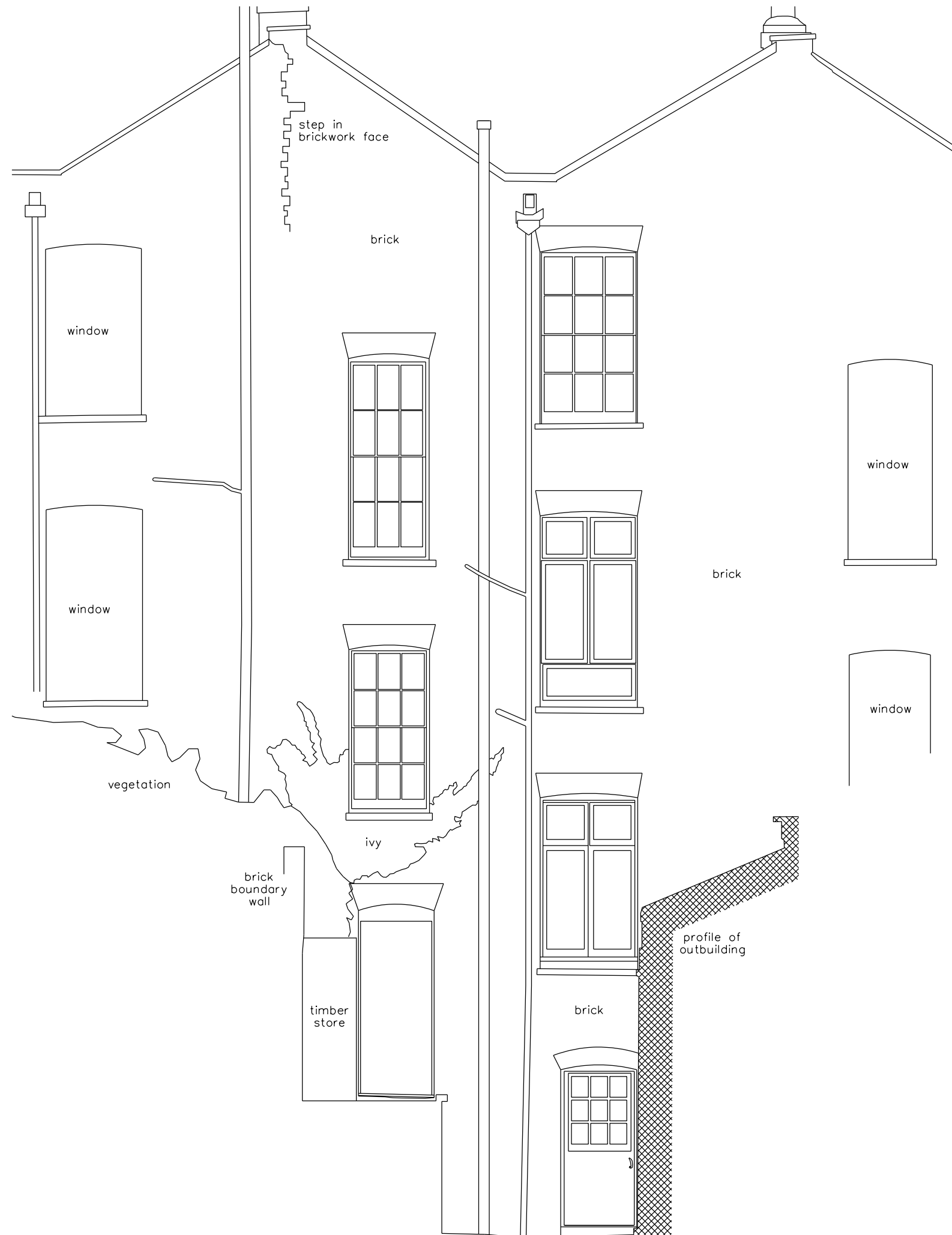
Drawing Number	Revision
A160_332	P1



Clive Sall Architecture Ltd.
Unit 2, Providence Yard,
Ezra Street, London, E2 7RJ







DO NOT SCALE FROM THIS DRAWING
Contractor to check and verify all dimensions on site prior to commencing work.
Any discrepancies to be reported to the architect immediately.
This drawing is copyrighted

[illegible]

Client
Philip Herrey

Project title
116 St Pancras Way
Kentish Town, London NW1 9NB

Status	Feasibility
--------	-------------

Structures
David Joseph Consulting

Services
Chapman Bathurst

Project manager	-
-----------------	---

Drawing Title
Existing Rear
Elevation

Date	Scale
14-01-13	1:50@ A3

Drawn	Checked	Authorised
-	-	-

Drawing Number	Revision
A160_371	I1

Copyright CLIVE SALL ARCHITECTURE LTD

